



PATIENT

Fenway Witkower

PRESENTING CLINICAL SIGNS

Acute onset of nasal discharge and malaise. Diagnosed with melanoma on lip. Concern for metastatic disease

SPECIES

Canine

RADIOGRAPHIC STUDY OF THE THORAX

RLR, LLR, VD

BREED

Golden Retriever

RADIOGRAPHIC FINDINGS

The body condition score is 7/9 with smooth alternating layers of fat and soft tissue opacity. Mild spondylosis is present.

SEX

MN

The lungs are in contact with the thoracic boundaries and the tips are pointed. The lobar vessels blurred, and peripheral bronchi are highlighted. The walls of the main bronchi are calcified.

The cranial mediastinum is of physiological size and opacity. The trachea diverges from the thoracic vertebrae and the carina is located at T6.

AGE

11 Years

The cardiac silhouette occupies 75% of the chest height and 3 intercostal spaces No chamber or outflow tract enlargement is evident.

RADIOGRAPHIC DIAGNOSIS

- Interstitial pattern
- Bronchial calcification
- Spondylosis, mild

INTERPRETED BY

Heike Rudolf, DVM,
Dr. med. Vet.,
DipECVDI DVR

INTERPRETATION OF THE FINDINGS & FURTHER RECOMMENDATIONS

I can see no lung nodules or lymph node enlargement.

The generalized interstitial lung pattern is a non-specific finding. Possible differential diagnoses for a true infiltrate include:

- Infection (bacterial, fungal e.g. candida, viral, Rickettsia, Spirochetes, parasitic)
- Inflammation (allergic e.g. eosinophilic bronchopneumonia and PIE, smoke inhalation)
- Edema
- DIC
- Fibrosis
- Tumor (e.g. lymphoma)

REFERRING VET

Shakira Jameson

INVOICE

47356

Further evaluation by means of tracheobronchoscopy with bronchoalveolar lavage should be considered.

DATE

9-7-21

Bronchial calcification is usually an age-related change but can also occur after bronchitis.

In case the nasal discharge persists, examination of the nose with CT and/or rhinoscopy is recommended to ensure no infection or tumor is present. The cervical lymph nodes should be included.



PATIENT

Fenway Witkower

SPECIES

Canine

BREED

Golden Retriever

SEX

MN

AGE

11 Years

INTERPRETED BY

Heike Rudolf, DVM,
Dr. med. Vet.,
DipECVDI DVR

HOSPITAL NAME

Paws and Claws Pet
Care

REFERRING VET

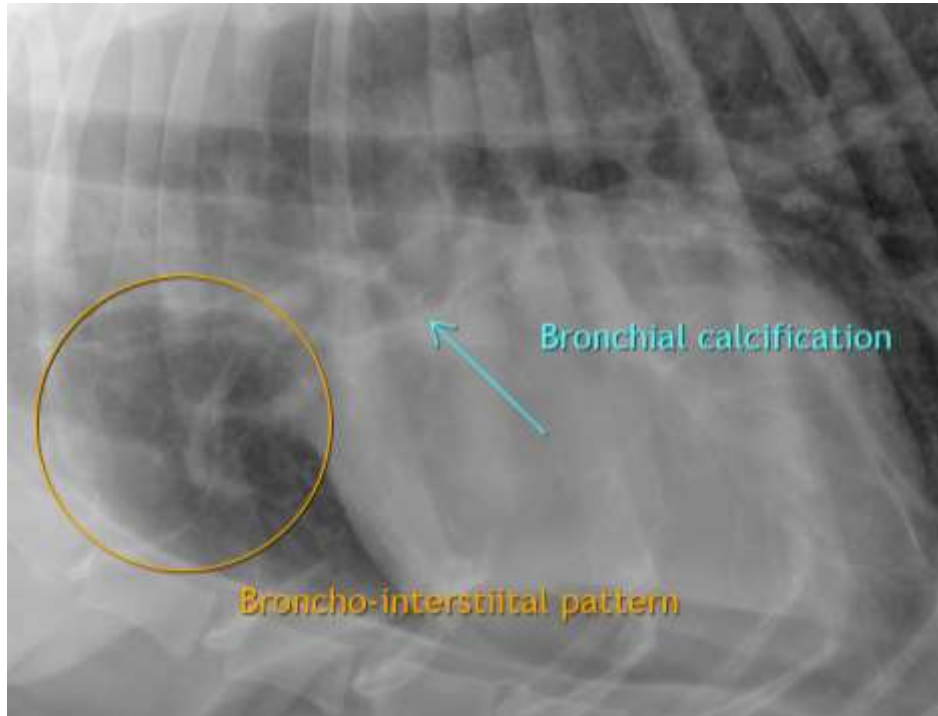
Shakira Jameson

INVOICE

47356

DATE

9-7-21



The information and recommendations provided are based on the images presented by the referring veterinarian. No evaluation can be communicated regarding pathology that was not visible in the image/video clips provided.

Thank you for this referral. If the clinical or image interpretation does not parallel your findings or if I can be of any further assistance please contact me.

Heike Rudolf, DVM, Dr. med. vet., DipECVDI, DVR
Dr.H.Rudorf@gmail.com