



PATIENT PRESENTING CLINICAL SIGNS

Tom Whitney History: p ate last night around 5pm, o woke up at 1am, o noticed p vomited all of his wet food, p is drinking water, p vomited about 4-5 times, p seems lethargic, diarrhea clear jelly like liquid o had covid 6 of last month

SPECIES

Abnormal PE/Chem/CBC/UA Results:

Feline

RADIOGRAPHIC STUDY OF THE ABDOMEN

BREED

The body condition score is 7/9 with smooth alternating layers of fat and soft tissue opacity.

DSH

Ventral spondylosis is present at the LS junction.

SEX

The abdominal detail is good; diaphragm and abdominal wall are intact.

Neutered Male

The liver is located within the costal arch and the caudo-ventral lobe is pointed.

The spleen appears physiological.

AGE

7 Years

The stomach contains a small amount of air; the small intestinal loops occupy the central abdomen and appear of homogeneous and physiological size. Colon and rectum are of soft tissue opacity.

Both renal shadows have a physiological size, shape and opacity. The bladder is located in the abdominal cavity and contains a moderate amount of homogeneous fluid opacity.

INTERPRETED BY

Heike Rudolf, DVM,
Dr. med. Vet.,
DipECVDI DVR

The region of the sublumbar lymph nodes shows a tubular structure with a convex cranial end level with L6, which is apparently located between a fluid filled colon and the sublumbar muscle.

RADIOGRAPHIC DIAGNOSIS

HOSPITAL NAME

DPC Veterinary H

- Tubular soft tissue structure pelvis
- LS spondylosis

INTERPRETATION OF THE FINDINGS & FURTHER RECOMMENDATIONS

REFERRING VET

Dr. White

Ultrasound is recommended to assess GIT wall size and layering as well as the sublumbar region. Alternatively, air can be introduced into the rectum to identify the position of the colon. Pancreatitis, food intolerance or viral gastro-enteritis and colitis may be present.

INVOICE

12963

DATE

9/6/21



PATIENT

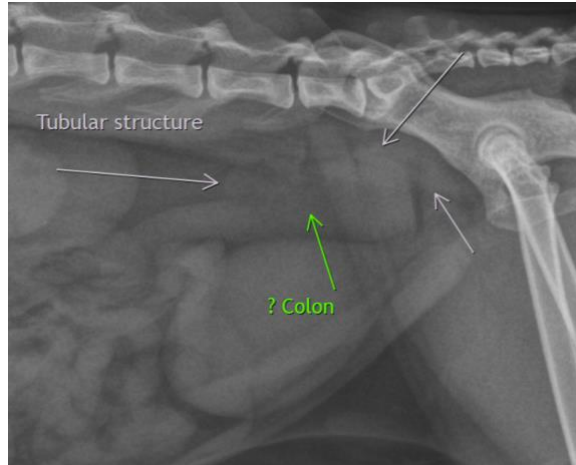
Tom Whitney

SPECIES

Feline

BREED

DSH



SEX

Neutered Male

The information and recommendations provided are based on the images presented by the referring veterinarian. No evaluation can be communicated regarding pathology that was not visible in the image/video clips provided.

AGE

7 Years

Thank you for this referral. If the clinical or image interpretation does not parallel your findings or if I can be of any further assistance please contact me.

Heike Rudolf, DVM, Dr. med. vet., DipECVDI, DVR
dr.h.rudorf@gmail.com

INTERPRETED BY

Heike Rudolf, DVM,
Dr. med. Vet.,
DipECVDI DVR

HOSPITAL NAME

DPC Veterinary H

REFERRING VET

Dr. White

INVOICE

12963

DATE

9/6/21