



PATIENT PRESENTING CLINICAL SIGNS

PATIENT Maia Mercado History: limping from right hind leg for on/off for 3 days, unsure of what happened, yesterday p was limping more, sometimes p would put weight on it, p plays with sister, when o touches paw p seems uncomfortable

SPECIES

Canine

BREED

Pitbull Mix

SEX

Female

AGE

6 Months

Abnormal PE/Chem/CBC/UA Results: Hydration: Appropriately hydrated Mentation: BAR, nervous - did like peanut butter EENT: No nasal discharge; clear no discharge OU; clean no exudate AU; No cough on tracheal palpation. Oral Cavity: No dental tartar present Lymph Nodes: Symmetrical, no changes in size, shape, consistency Skin: Good hair coat, no signs of ectoparasites. No lesions. CV/Respiratory: No murmur/arrhythmia or crackles/wheezing auscultated. Synchronous pulses, normal rate. Normal bronchovesicular sounds. Abd/GI: Soft non painful abdomen, no organomegaly, no abnormalities on abdominal palpation Uro/Perineum: N Musculoskeletal: Abnormal ambulation, grade 3/4 right hind lameness noted. MPL RH grade 4/4, mild stifle effusion RH. Good musculature. BCS 5/9 Neurological: Appropriate

RADIOGRAPHIC STUDY OF THE STIFLES

The skin surfaces are smooth and the muscles appear to be symmetrically developed.

Skeletal immaturity is noted. The skeletal structures are well mineralized, with physiological cortico-medullary development and differentiation.

The right stifle joint has smooth subchondral bone surfaces. The cranial fat pad is reduced and the fascial plains obscured by a soft tissue opacity within the joint. New bone formation is not evident.

The patella is superimposed onto the medial condyle on the cranio-caudal view.

The left stifle joint appears physiological; the patella is superimposed onto the medial condyle on the cranio-caudal view.

INTERPRETED BY

Heike Rudolf, DVM,
Dr. med. Vet.,
DipECVDI DVR

HOSPITAL NAME

DPC Veterinary H

RADIOGRAPHIC DIAGNOSIS

REFERRING VET

Dr. Duke

- Joint effusion right, mild
- Patella luxation right>left

INTERPRETATION OF THE FINDINGS & FURTHER RECOMMENDATIONS

INVOICE

12960

Manual examination of the position of both patellae is recommended as radiographs are unreliable for the low-grade disease. The mild stifle effusion could be the result of cruciate ligament damage and the stifles may have to be examined under sedation to elicit a cranial drawer. Should conservative treatment not eliminate the clinical signs, surgery will have to be considered.

DATE

9/6/21



PATIENT

Maia Mercado

SPECIES

Canine

BREED

Pitbull Mix

SEX

Female

AGE

6 Months

INTERPRETED BY

Heike Rudolf, DVM,
Dr. med. Vet.,
DipECVDI DVR

HOSPITAL NAME

DPC Veterinary H

REFERRING VET

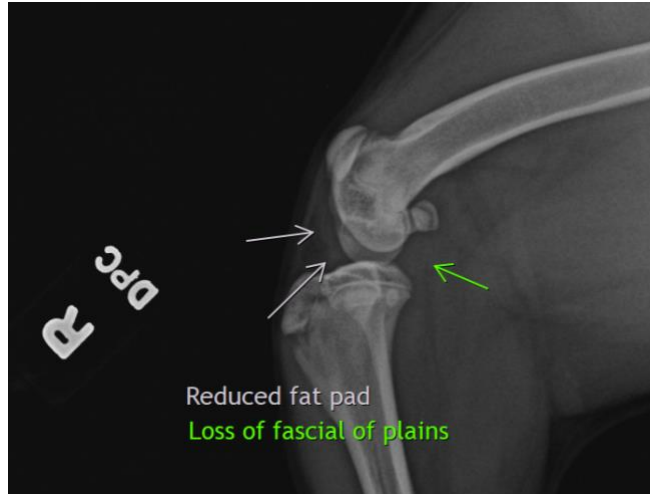
Dr. Duke

INVOICE

12960

DATE

9/6/21



The information and recommendations provided are based on the images presented by the referring veterinarian. No evaluation can be communicated regarding pathology that was not visible in the image/video clips provided.

Thank you for this referral. If the clinical or image interpretation does not parallel your findings or if I can be of any further assistance please contact me.

Heike Rudolf, DVM, Dr. med. vet., DipECVDI, DVR
dr.h.rudorf@gmail.com