



PATIENT

Buster Bandini

PRESENTING CLINICAL SIGNS

Hematuria for the past few days improving with clavamox. Intact and hx of enlarged prostate about 1 year ago. Otherwise acting fine. E/D/D fine and no V/D/C/S. Active and BAR. Abnormal PE/Chem/CBC/UA Results: All results pending but PE WNL.

SPECIES

Canine

RADIOGRAPHIC FINDINGS

Abdomen

BREED

English Bulldog

BCS = 7/9 with a pendulous ventral abdominal wall and a moderate amount of retroperitoneal fat.

T12 is wedge shaped. Spondylosis is present T11/12.

SEX

Male Intact

The abdominal detail is good; the diaphragm is intact; the liver is located within the costal arch and the caudo-ventral lobe is pointed.

The spleen appears physiological.

AGE

6.5 Years

The stomach contains a moderate amount of food. The small intestinal loops occupy the central right abdomen, and the luminal size varies slightly due to the different amounts of gas. On all images two intestinal loops are C-shaped and in close proximity to one another level with L5/6, having a larger diameter than the rest on the VD view. The terminal colon and rectum contain a moderate amount of unformed fecal matter.

INTERPRETED BY

Heike Rudolf, DVM,
Dr. med. Vet.,
DipECVDI DVR

The L renal shadow is of physiological size, shape and opacity; the surfaces are smooth. The R kidney is obscured by intestinal loops. The bladder is located in the abdominal cavity and contains a small amount of homogeneous fluid opacity.

HOSPITAL NAME

Northvale Veterinary
Clinic

The prostate gland is table tennis sized and of homogenous opacity, displacing the bladder cranially.

The sublumbar lymph region appears physiological.

REFERRING VET

Dr. Stefanie Simon

RADIOGRAPHIC DIAGNOSIS

- Mild, localized ileus
- Prostatomegaly, mild
- Congenital vertebral anomaly
- Spondylosis

INVOICE

47359

INTERPRETATION OF THE FINDINGS & FURTHER RECOMMENDATIONS

DATE

9-4-21

Variation in intestinal diameter without clinical signs represents a normal variation. Prostatic size for an intact male dog is physiological. However, should it be hard on palpation a prostatic tumor is possible. Abdominal ultrasound is recommended to rule out bladder neck, urethral and prostatic tumor. Prostatic hematocysts can be combined with prostatic hyperplasia which may explain the clinical signs. Urinary culture and cytology should be obtained if it has not already been done.



PATIENT

Buster Bandini

SPECIES

Canine

BREED

English Bulldog

SEX

Male Intact

AGE

6.5 Years

INTERPRETED BY

Heike Rudolf, DVM,
Dr. med. Vet.,
DipECVDDI DVR

HOSPITAL NAME

Northvale Veterinary
Clinic

REFERRING VET

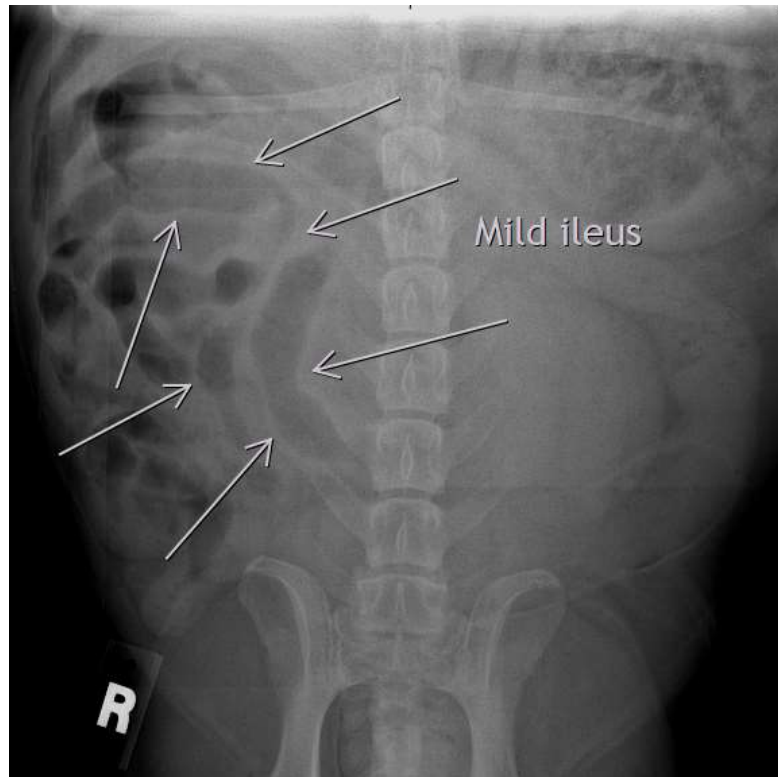
Dr. Stefanie Simon

INVOICE

47359

DATE

9-4-21



The information and recommendations provided are based on the images presented by the referring veterinarian. No evaluation can be communicated regarding pathology that was not visible in the image/video clips provided.

Thank you for this referral. If the clinical or image interpretation does not parallel your findings or if I can be of any further assistance please contact me.

Heike Rudolf, DVM, Dr. med. vet., DipECVDDI, DVR
Dr.H.Rudorf@gmail.com