



**PATIENT PRESENTING CLINICAL SIGNS**

**Diesel Barry** History: 2 week intermediate right front lameness. Worse at home than in clinic. Decrease range of motion with elbows.

**SPECIES RADIOGRAPHIC STUDY OF THE ELBOWS**

**Canine** The bones are well mineralized, have a normal trabecular structure. Cortical-medullary development and differentiation of the long bones are physiological.

**BREED Elbows**

**English Bulldog** A moderate amount of new bone formation is located on the cranial radial head which appears layered on the right and smooth on the left leg. A small bone spur is present on both medial epicondyles and the outline of both anconeal processes are slightly irregular. New bone formation is also present on both medial epicondyles.

**SEX**

Neutered Male

**RADIOGRAPHIC DIAGNOSIS**

- Bilateral elbow arthrosis

**AGE INTERPRETATION OF THE FINDINGS & FURTHER RECOMMENDATIONS**

**9 Years 8 Months** The bony changes are bilateral and thus do not explain the unilateral lameness. Possible differential diagnoses include acute arthritis with effusion after trauma, damage to the ligaments of the elbow, flexor myositis and neural pathology (e.g. neuritis, tumour of the brachial plexus). Should the dog not respond to conservative treatment, cross sectional imaging is recommended.

**INTERPRETED BY**

Heike Rudorf, DVM,  
Dr. med. Vet.,  
DipECVDI DVR

**HOSPITAL NAME**

All Creatures AH of  
SH, Inc.

**REFERRING VET**

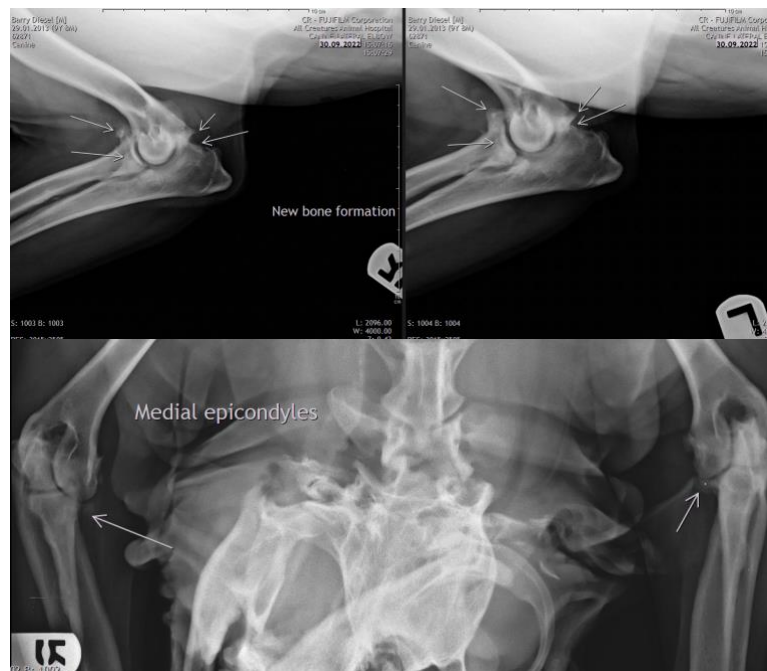
Dr. Saylor

**INVOICE**

17522

**DATE**

9/30/22





**PATIENT**

Diesel Barry

**The information and recommendations provided are based on the images presented by the referring veterinarian/sonographer. No evaluation can be communicated regarding pathology that was not visible in the image/video clips provided.**

**SPECIES**

Canine

Thank you for this referral. If the clinical or image interpretation does not parallel your findings or if I can be of any further assistance please contact me.

**Heike Rudorf**, DVM, Dr. med. vet., DipECVDI, DVR  
dr.h.rudorf@gmail.com

**BREED**

English Bulldog

**SEX**

Neutered Male

**AGE**

9 Years 8 Months

**INTERPRETED BY**

Heike Rudorf, DVM,  
Dr. med. Vet.,  
DipECVDI DVR

**HOSPITAL NAME**

All Creatures AH of  
SH, Inc.

**REFERRING VET**

Dr. Saylor

**INVOICE**

17522

**DATE**

9/30/22