



PATIENT PRESENTING CLINICAL SIGNS

407 Wei History: soft stools for 7 days, no other concerns
 Abnormal PE/Chem/CBC/UA Results: PE- not significant, BW shows mild leukopenia rest is WNL

SPECIES RADIOGRAPHIC STUDY OF THE THORAX

Feline The body condition score is 6/9 with poor abdominal detail.

Skeletal immaturity compatible with the given age is noted. The bony structures are within normal limits.

BREED

Maine Coon The liver appears to be located within the costal arch and the caudo-ventral lobe is pointed.
 The spleen does not appear enlarged.

SEX

Male The stomach contains a small amount of air; distribution and size of the small intestinal loops appear physiological. Colon and rectum contain a moderate amount of gas and the ascending colon has a similar filling on all views.

AGE

13 Weeks Assessment of both renal shadows is difficult. The bladder is located in the abdominal cavity and contains a moderate amount of homogeneous fluid opacity.
 The sublumbar region appears physiological.

RADIOGRAPHIC DIAGNOSIS

- Reduced visibility of renal shadows
- Gas in stomach and colon

INTERPRETED BY

Heike Rudorf, DVM,
 Dr. med. Vet.,
 DipECVDI DVR

INTERPRETATION OF THE FINDINGS & FURTHER RECOMMENDATIONS

I can see no signs of ileus. Food intolerance is a possibility for soft stool and a change of diet may help. Abdominal ultrasound is recommended to assess renal architecture and intestinal wall thickness and layering. This will help rule out colitis.

HOSPITAL NAME

St. Catharine's AH

REFERRING VET

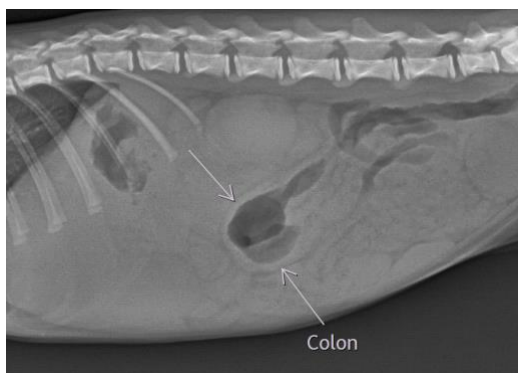
Dr. Gokhale

INVOICE

17526

DATE

9/30/22





PATIENT The information and recommendations provided are based on the images presented by the referring veterinarian/sonographer. No evaluation can be communicated regarding pathology that was not visible in the image/video clips provided.

407 Wei

Thank you for this referral. If the clinical or image interpretation does not parallel your findings or if I can be of any further assistance please contact me.

SPECIES

Feline **Heike Rudolf**, DVM, Dr. med. vet., DipECVDI, DVR
dr.h.rudorf@gmail.com

BREED

Maine Coon

SEX

Male

AGE

13 Weeks

INTERPRETED BY

Heike Rudolf, DVM,
Dr. med. Vet.,
DipECVDI DVR

HOSPITAL NAME

St. Catharine's AH

REFERRING VET

Dr. Gokhale

INVOICE

17526

DATE

9/30/22