



PATIENT

Maisie Esser

PRESENTING CLINICAL SIGNS

Chronic recurrent diarrhea since July. Blood in stool, recent vomiting noted this week. Recent fecal analysis negative. Senior profile from July 14 2021 all WNL. Physical exam WNL. Non painful on abdominal palpation. Digital rectal exam mucous on exam glove, colon empty. Abnormal PE/Chem/CBC/UA Results: Pending CBC/Chem/UA and specCPL

SPECIES

Canine

RADIOGRAPHIC FINDINGS

Abdomen

BREED

Golden Retriever

BCS = 7/9 with smooth alternating layers of fat and soft tissue opacity.

The vertebrae are well mineralized with good trabecular structure and smooth surfaces. The disc spaces appear homogeneous in width.

SEX

Female Spayed

The abdominal detail is good; the diaphragm is intact; the liver is located within the costal arch and the caudo-ventral lobe is pointed.

The tail of the spleen is located between ventral liver lobe and pylorus, slightly displacing the latter dorsally.

AGE

9

The stomach contains a moderate amount of air; the small intestinal loops occupy the central abdomen and contain variable amounts of gas. Colon and rectum contain a moderate amount of fecal matter. The ventral wall of the terminal colon is thicker (0.28cm) than the dorsal wall (0.14cm)

INTERPRETED BY

Heike Rudolf, DVM,
Dr. med. Vet.,
DipECVDDI DVR

The urinary tract appears physiological.

The sublumbar lymph region appears physiological.

HOSPITAL NAME

Sierra Pet Clinic

RADIOGRAPHIC DIAGNOSIS

- Thickening of colonic wall

REFERRING VET

L. Ferrera

INTERPRETATION OF THE FINDINGS & FURTHER RECOMMENDATIONS

Abdominal ultrasound to assess gastro-intestinal wall thickness and layering is recommended. This should be followed by proctoscopy to obtain a biopsy so that tumor and inflammation can be differentiated.

INVOICE

47345

DATE

9-3-21



PATIENT

Maisie Esser

SPECIES

Canine

BREED

Golden Retriever

SEX

Female Spayed

AGE

9

INTERPRETED BY

Heike Rudorf, DVM,
Dr. med. Vet.,
DipECVDDI DVR

HOSPITAL NAME

Sierra Pet Clinic

REFERRING VET

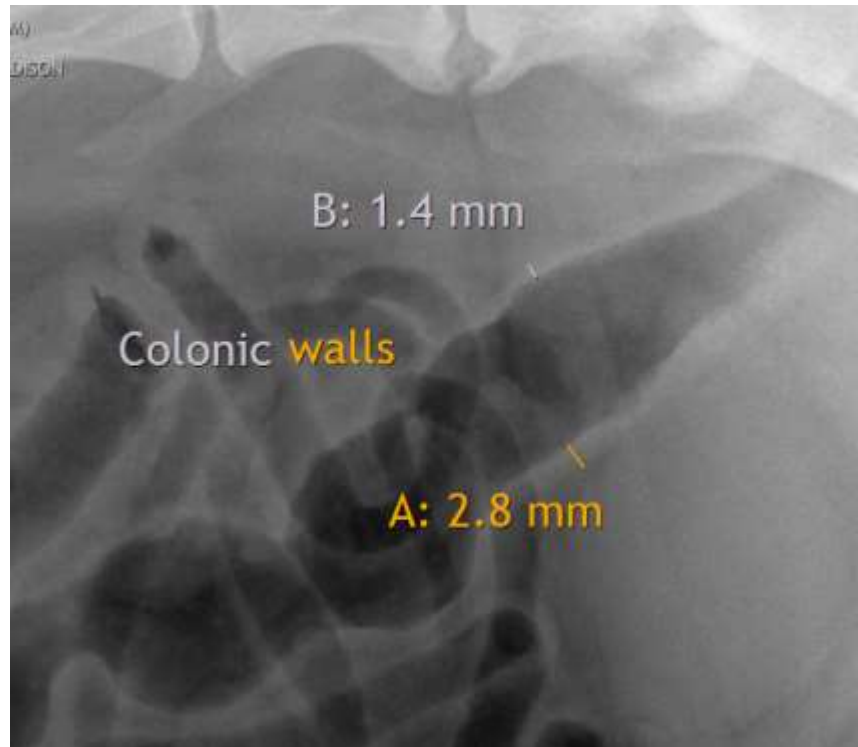
L. Ferrera

INVOICE

47345

DATE

9-3-21



The information and recommendations provided are based on the images presented by the referring veterinarian. No evaluation can be communicated regarding pathology that was not visible in the image/video clips provided.

Thank you for this referral. If the clinical or image interpretation does not parallel your findings or if I can be of any further assistance please contact me.

Heike Rudorf, DVM, Dr. med. vet., DipECVDDI, DVR
Dr.H.Rudorf@gmail.com