

**PATIENT**

Marley Ludwig

PRESENTING CLINICAL SIGNS

History: checking hips and elbows before breeding and before sending to OFA
Abnormal PE/Chem/CBC/UA Results:

SPECIES

Canine

RADIOGRAPHIC STUDY OF PELVIS AND ELBOWS

The skeletal structures are well mineralized, with physiological cortico-medullary development and differentiation.

Pelvis**BREED**

Golden Retriever

The center of the right femoral head is located just lateral to the dorsal acetabular edge, the one of the left is located just medial to it. The medial joint space on the right is slightly wide. No new bone formation is evident.

SEX

Female

Right Elbow

The joints are congruent with smooth subchondral bone surfaces. Joint swelling is not apparent.

Left Elbow**AGE**

1 Year 1 Month

The joints are congruent with smooth subchondral bone surfaces. Joint swelling is not apparent.

RADIOGRAPHIC DIAGNOSIS

- Mild HD, bilateral

INTERPRETED BY

Heike Rudolf, DVM,
Dr. med. Vet.,
DipECVDI DVR

INTERPRETATION OF THE FINDINGS & FURTHER RECOMMENDATIONS

The pelvis is slightly tilted to the right side (wing of ilium slightly larger, obturator foramen slightly smaller than on the left) thus the position of the center of the femoral condyles is not quite accurate. In a completely straight view they would probably be superimposed onto their respective dorsal acetabular edge. Both elbow joint appear physiological though only a CT examination can rule out sclerosis or lucent lines in the coronoids.

HOSPITAL NAME

Elizabeth AH

REFERRING VET

Leon Anderson, DVM

INVOICE

13254

DATE

9/24/21



PATIENT

Marley Ludwig

SPECIES

Canine

BREED

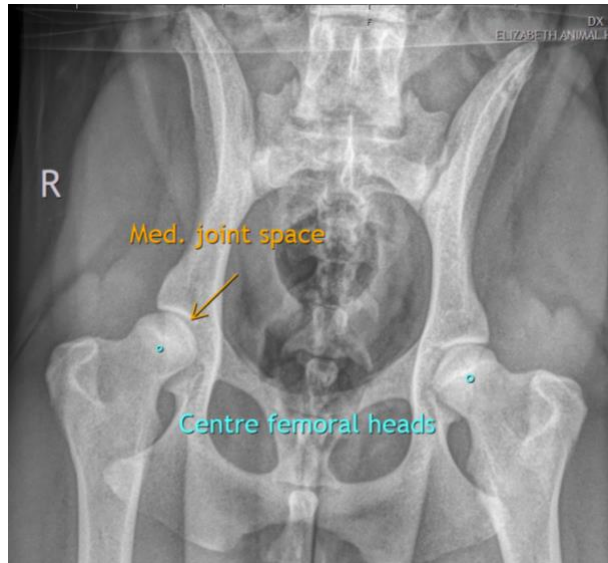
Golden Retriever

SEX

Female

AGE

1 Year 1 Month



The information and recommendations provided are based on the images presented by the referring veterinarian. No evaluation can be communicated regarding pathology that was not visible in the image/video clips provided.

Thank you for this referral. If the clinical or image interpretation does not parallel your findings or if I can be of any further assistance please contact me.

Heike Rudolf, DVM, Dr. med. vet., DipECVDI, DVR
dr.h.rudorf@gmail.com

INTERPRETED BY

Heike Rudolf, DVM,
Dr. med. Vet.,
DipECVDI DVR

HOSPITAL NAME

Elizabeth AH

REFERRING VET

Leon Anderson, DVM

INVOICE

13254

DATE

9/24/21