



**PATIENT PRESENTING CLINICAL SIGNS**

Barney Steffen History: IRIS CKD Stage 1 workup looking for uroliths, etc.

**SPECIES**

Canine

**RADIOGRAPHIC STUDY OF THE ABDOMEN**

The body condition score is 7/9 with smooth alternating layers of fat and soft tissue opacity.

**BREED**

Chow Chow

The bones are well mineralized with good trabecular structure and smooth surfaces. The disc spaces appear homogeneous in width.

The abdominal detail is good; diaphragm and abdominal wall are intact.

**SEX**

Neutered Male

The liver is located within the costal arch and the caudo-ventral lobe is pointed.

The spleen appears physiological.

**AGE**

3 Years

The stomach is distended with a mixture of fluid and air; in left lateral recumbency the air outlines the gastric rugae.

The small intestinal loops are displaced caudally by the stomach and appear of homogeneous and physiological size. Terminal colon and rectum contain a moderate amount of unformed fecal matter. The colon is superimposed onto the dorsal bladder and the rectum fills almost the entire pelvic canal indicating a small prostate.

**INTERPRETED BY**

Heike Rudolf, DVM,  
Dr. med. Vet.,  
DipECVDI DVR

Both renal shadows are partially obscured by small intestinal loops but appear to have a physiological length, shape and opacity; renal height appears reduced. The bladder is located in the abdominal cavity and contains a large amount of homogeneous fluid opacity.

**HOSPITAL NAME**

Sierra Pet Clinic

The region of the sublumbar lymph nodes appears physiological.

**RADIOGRAPHIC DIAGNOSIS**

- Possible reduction in renal height/width
- Distended stomach

**REFERRING VET**

D. Swalander

**INTERPRETATION OF THE FINDINGS & FURTHER RECOMMENDATIONS**

The position of the kidneys within the retroperitoneal space may be slightly oblique, which would reduce the renal width on the lateral view. Only the VD will show the exact size but usually, as in this dog, small intestinal loops obscure the central abdominal region and thus the renal shadows.

**INVOICE**

13248

The gastric distension may be the result of polydipsia and, in combination with a full bladder, this may be the result of early renal failure. Differential diagnoses for polydipsia are Diabetes mellitus and Cushing's disease but without hepatic enlargement these are less likely. The visibility of rugae due to gastric air is not unusual but is association with CKD rugal calcification should be considered. This and early renal changes, such as an undulating outline, are best detected with ultrasound which will also

**DATE**

9/24/21



**PATIENT** highlight very small calcium deposits. I thus recommend an ultrasound examination at the next check up.

Barney Steffen

**SPECIES**

Canine

**BREED**

Chow Chow

**SEX**

Neutered Male

**AGE**

3 Years

**INTERPRETED BY**

Heike Rudolf, DVM,  
Dr. med. Vet.,  
DipECVDDI DVR

**HOSPITAL NAME**

Sierra Pet Clinic

**REFERRING VET**

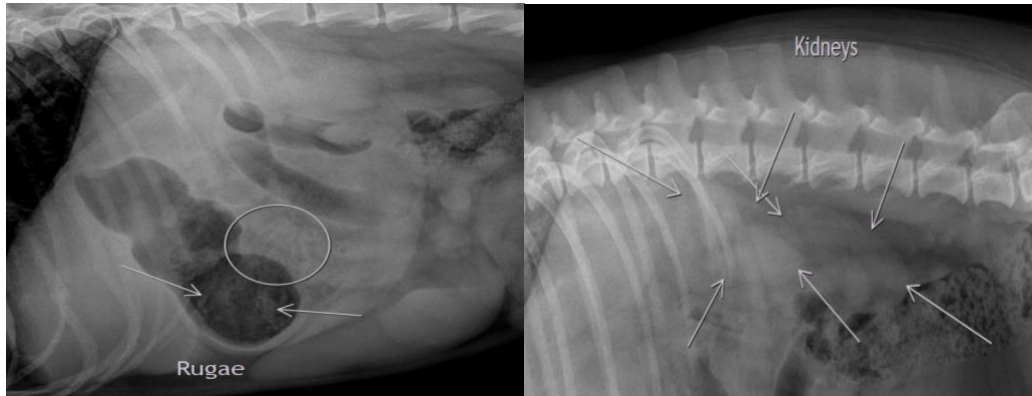
D. Swalander

**INVOICE**

13248

**DATE**

9/24/21



The information and recommendations provided are based on the images presented by the referring veterinarian. No evaluation can be communicated regarding pathology that was not visible in the image/video clips provided.

Thank you for this referral. If the clinical or image interpretation does not parallel your findings or if I can be of any further assistance please contact me.

**Heike Rudolf, DVM, Dr. med. vet., DipECVDDI, DVR**  
dr.h.rudorf@gmail.com