



PATIENT PRESENTING CLINICAL SIGNS

Tucker Edwards History: Coughing on and off for the last month. Last week stopped wanting to eat. Breathing heavier than normal. Coughing.

SPECIES RADIOGRAPHIC STUDY OF THE ABDOMEN

Canine The body condition score is 6/9 with smooth alternating layers of fat and soft tissue opacity. The bony structures appear physiological.

BREED The visible lung lobes are in contact with the thoracic boundaries and the tips are pointed. The lobar vessels are clearly visible to the tertiary branches. The bronchial tree is thin walled and tapers uniformly towards the periphery.

GSP The cardiac silhouette occupies 75% of the chest height.

SEX The fat in the cranio-ventral abdomen appears striated in left lateral recumbency. The liver is located within the costal arch.

Neutered Male The spleen appears large and appears to displace the pylorus dorsally.

AGE The stomach contains a mixture of food and air; distribution, size and contents of the small intestinal loops differs on all views. The terminal colon contains formed feces.

9 Years Both renal shadows have a physiological size, shape and opacity. The bladder shadow is small and located just cranial to the pubic brim.

INTERPRETED BY The sublumbar region appears physiological.

Heike Rudolf, DVM, Dr. med. Vet., DipECVDI DVR

RADIOGRAPHIC DIAGNOSIS

- Splenomegaly
- Striated fat in cranial abdomen

HOSPITAL NAME INTERPRETATION OF THE FINDINGS & FURTHER RECOMMENDATIONS

Valley Veterinary Svcs. The striated appearance of the fat can represent an artefact due to wet fur or ultrasound gel. In case it is a true finding, inflammation or edema of the mesentery have to be considered. Both can be associated with pancreatic disease or carcinomatosis. Splenic hematoma or hemangiosarcoma can bleed and result in trapped mesenteric hemorrhage. Abdominal ultrasound is recommended to identify these changes and to assess the splenic architecture. Samples may need to be obtained.

REFERRING VET TECHNICAL COMMENTS

Tiffani Crum I cannot find thoracic images and have thus reported on the views I had available. The age given on the images is 3 years, on the form it is 9 years.

INVOICE

17449

DATE

9/23/22



PATIENT

Tucker Edwards

SPECIES

Canine

BREED

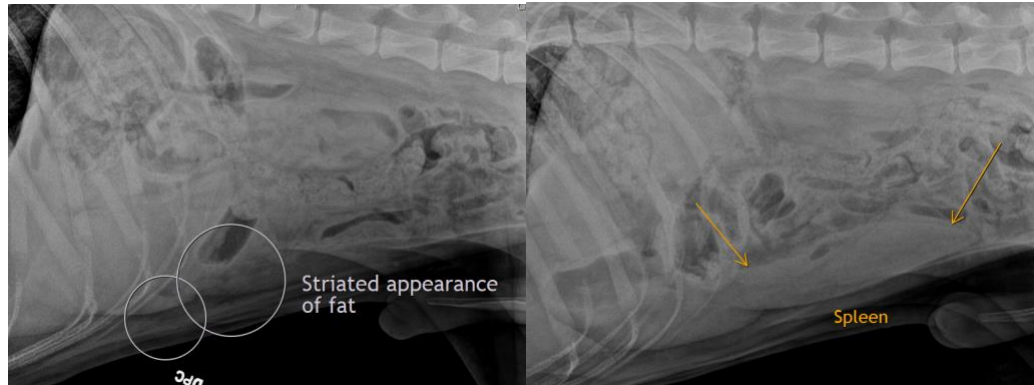
GSP

SEX

Neutered Male

AGE

9 Years



The information and recommendations provided are based on the images presented by the referring veterinarian/sonographer. No evaluation can be communicated regarding pathology that was not visible in the image/video clips provided.

Thank you for this referral. If the clinical or image interpretation does not parallel your findings or if I can be of any further assistance please contact me.

Heike Rudorf, DVM, Dr. med. vet., DipECVDI, DVR
dr.h.rudorf@gmail.com

INTERPRETED BY

Heike Rudorf, DVM,
Dr. med. Vet.,
DipECVDI DVR

HOSPITAL NAME

Valley Veterinary
Srvcs.

REFERRING VET

Tiffani Crum

INVOICE

17449

DATE

9/23/22