



PATIENT PRESENTING CLINICAL SIGNS

PATIENT Nova Gilbertson **PRESENTING CLINICAL SIGNS** History: Intermittent pain in hind end. More severe LHL. Tight left quadriceps on firm palpation of high quads and medial aspect of wing of ileum. Resolved with NSAIDs and rest. Then reoccurs with return to normal activity.

SPECIES Abnormal PE/Chem/CBC/UA Results: n/a

SPECIES Canine **RADIOGRAPHIC STUDY OF THE PELVIS**

BREED The right femoral musculature is reduced.

BREED Husky All bones are well mineralized, have a normal trabecular structure and a smooth surface. Cortical-medullary development and differentiation of the long bones are physiological.

SEX The centre of both femoral heads is located just medial to the respective dorsal acetabular edge. Both hip joints appear congruent with even subchondral bone surfaces. No new bone formation is evident.

SEX Spayed Female **RADIOGRAPHIC DIAGNOSIS**

- Muscle atrophy right worse than left

AGE INTERPRETATION OF THE FINDINGS & FURTHER RECOMMENDATIONS

AGE 3 Years I can see no changes that would explain the clinical signs or the loss of muscle mass. Further examinations are thus necessary to rule out disc disease, diseases of the lumbar plexus (e.g. sciatic neuritis or tumour), myositis (e.g. gastrocnemius bellies) and tendinitis (e.g. flexor tendons). Cross sectional imaging is recommended whereby contrast CT is likely more readily available than MRI.

INTERPRETED BY

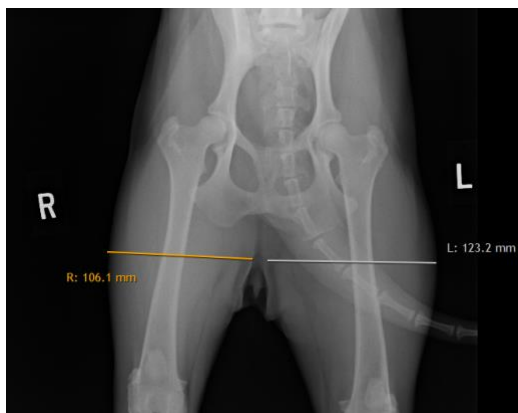
Heike Rudolf, DVM,
Dr. med. Vet.,
DipECVDI DVR

HOSPITAL NAME

Lac Ste. Anne VS

REFERRING VET

Dr. K. Macintosh



INVOICE

17447

DATE

9/23/22

The information and recommendations provided are based on the images presented by the referring veterinarian/sonographer. No evaluation can be communicated regarding pathology that was not visible in the image/video clips provided.

Thank you for this referral. If the clinical or image interpretation does not parallel your findings or if I can be of any further assistance please contact me.



PATIENT

Nova Gilbertson **Heike Rudolf**, DVM, Dr. med. vet., DipECVDI, DVR
dr.h.rudorf@gmail.com

SPECIES

Canine

BREED

Husky

SEX

Spayed Female

AGE

3 Years

INTERPRETED BY

Heike Rudolf, DVM,
Dr. med. Vet.,
DipECVDI DVR

HOSPITAL NAME

Lac Ste. Anne VS

REFERRING VET

Dr. K. Macintosh

INVOICE

17447

DATE

9/23/22