



PATIENT

Boomer Sherrill

PRESENTING CLINICAL SIGNS

Rear limb discomfort has been worsening recently since pt jumped out of the car and 'bumped' the body of the car a few weeks ago.
Abnormal PE/Chem/CBC/UA Results: ALKP is elevated at 414.

SPECIES

Canine

RADIOGRAPHIC STUDY OF PELVIS, STIFLES AND L-SPINE

2x lateral pelvis opened legs, R+L lateral stifle, VD pelvis, 2 orthogonal views of the L-spine

BREED

Husky

RADIOGRAPHIC FINDINGS

A small, round, metal structure is present lateral to the L ilium. The muscles of both hind legs appear poorly developed.

SEX

Male Neutered

The skeletal structures are well mineralized, with physiological cortico-medullary development and differentiation.

Pelvis

AGE

13

The legs are insufficiently extended (as is explained in the history). Both hip joints appear congruent with even subchondral bone surfaces. Slightly fluffy new bone formation is evident on the lateral aspect of the left acetabular part of the ilium.

Stifles

INTERPRETED BY

Heike Rudolf, DVM,
Dr. med. Vet.,
DipECVDI DVR

The L stifle joint has smooth subchondral bone surfaces, and the centre of the femoral condyles is in line with the intercondylar eminence. The cranial fat pad has a physiological size, and the caudal fascial plains are in a physiological position. New bone formation is not evident, and the patella is located in its groove.

HOSPITAL NAME

Sierra Pet Clinic

The R stifle joint has smooth subchondral bone surfaces, and the centre of the femoral condyles is in line with the intercondylar eminence. It shows a decrease of the cranial fat pad and caudal displacement of the fascial plains. Small osteophytes are located on the distal pole of the patella.

REFERRING VET

Dave Swalander

L-Spine

No signs of aggressive osteolysis have been identified.

Eight lumbar vertebrae are present. Bridging spondylosis affects almost all vertebrae. The cranial vertebrae show smooth new bone formation of the articular facets.

INVOICE

47510

The L6-8-disc spaces are reduced.

The L6/7 intervertebral foramen is decreased from ventrally. The L7/8 end plates are sclerotic.

DATE

9-23-21

**PATIENT**

Boomer Sherrill

RADIOGRAPHIC DIAGNOSIS

R stifle

- Effusion
- Small osteophytes

SPECIES

Canine

Muscle atrophy hind legs
Facet arthropathy
Reduced L6-8 disc spaces

BREED

Husky

Incidental findings

- Shot gun pellet on L
- Spondylosis
- Transitional vertebrae

SEX

Male Neutered

INTERPRETATION OF THE FINDINGS & FURTHER RECOMMENDATIONS

The changes are numerous and may all have a part in the clinical signs. The stifle effusion is most likely due to cruciate disease. In case no cranial drawer is present, there may still be a partial rupture.

AGE

13

To assess the disc spaces more accurately and identify cord compression, a CT examination is recommended. An inability to extend the hind legs may be due to muscle contracture/fibrosis. The new bone on the acetabulum could be due to trauma or the result of a low-grade infectious process. Contrast CT can help differentiate this.

INTERPRETED BY

Heike Rudorf, DVM,
Dr. med. Vet.,
DipECVDI DVR

HOSPITAL NAME

Sierra Pet Clinic

REFERRING VET

Dave Swalander

INVOICE

47510

DATE

9-23-21



PATIENT

Boomer Sherrill

SPECIES

Canine

BREED

Husky

SEX

Male Neutered

AGE

13

INTERPRETED BY

Heike Rudorf, DVM,
Dr. med. Vet.,
DipECVDDI DVR

HOSPITAL NAME

Sierra Pet Clinic

REFERRING VET

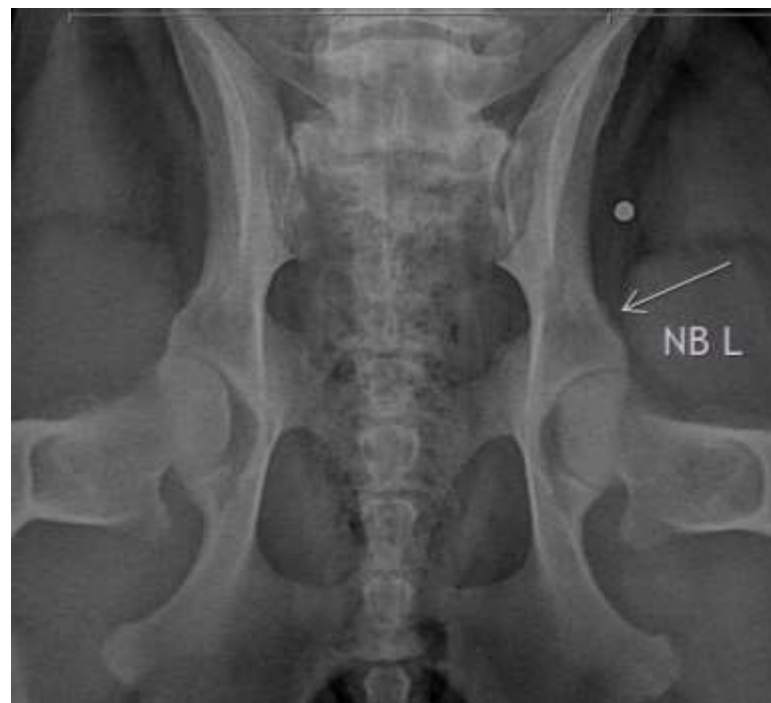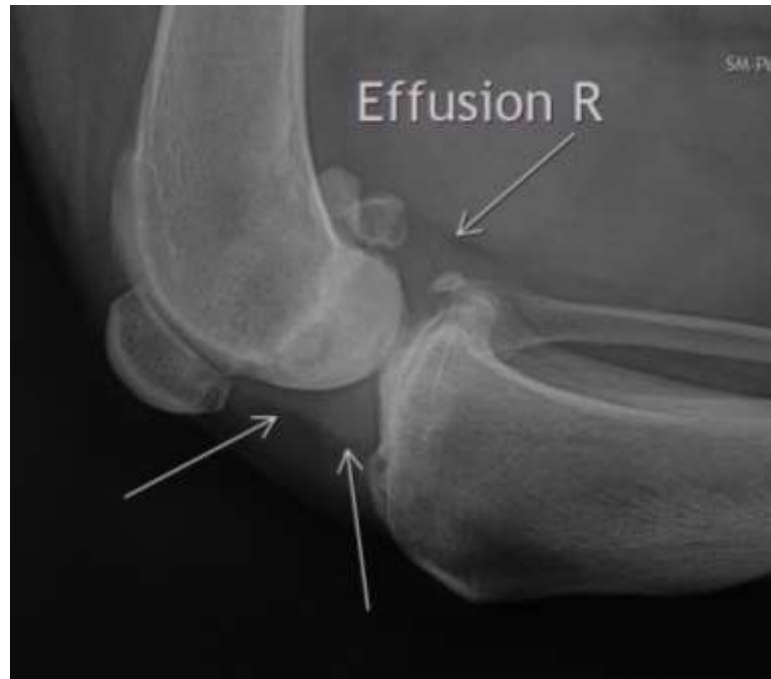Dave Swalander

INVOICE

47510

DATE

9-23-21





PATIENT

Boomer Sherrill

SPECIES

Canine

BREED

Husky

SEX

Male Neutered

AGE

13

INTERPRETED BY

Heike Rudolf, DVM,
Dr. med. Vet.,
DipECVDDI DVR

HOSPITAL NAME

Sierra Pet Clinic

REFERRING VET

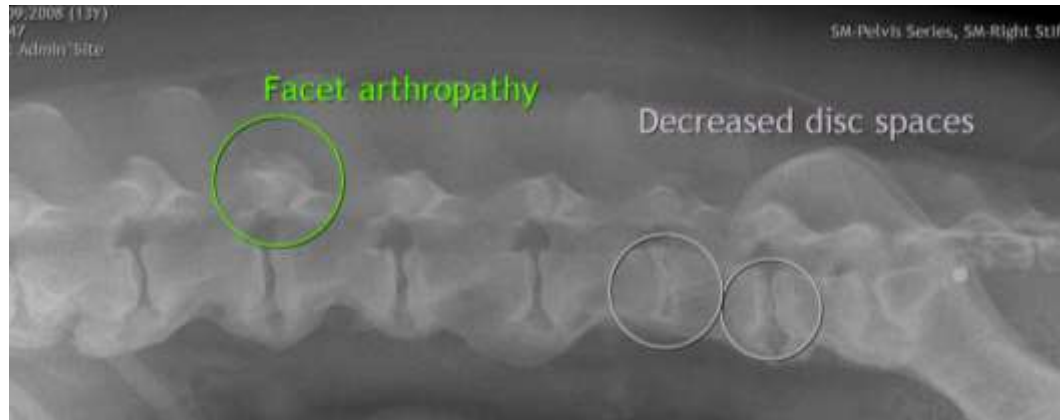
Dave Swalander

INVOICE

47510

DATE

9-23-21



The information and recommendations provided are based on the images presented by the referring veterinarian. No evaluation can be communicated regarding pathology that was not visible in the image/video clips provided.

Thank you for this referral. If the clinical or image interpretation does not parallel your findings or if I can be of any further assistance please contact me.

Heike Rudolf, DVM, Dr. med. vet., DipECVDDI, DVR
Dr.H.Rudorf@gmail.com