



PATIENT PRESENTING CLINICAL SIGNS

Summer Bohlen History: 2lb weight loss noted over 2 months, eating fine. Coughing daily but rarely brings hairballs up. Has several year history of hairballs/coughing. BW from June 2022 WNL

SPECIES RADIOGRAPHIC STUDY OF THE THORAX

Feline The body condition score is 6/9 with smooth alternating layers of fat and soft tissue opacity.

BREED The disc space T5/6 is decreased. Ventral spondylosis is located on the endplates of the middle thoracic vertebrae.

DSH The degree of pulmonary expansion is very good. The lungs are in contact with the thoracic boundaries and the tips are pointed. A moderately large gap is present between caudal heart border and dome of the diaphragm on all views. The diaphragmatic outline is slightly wavy. An almost circular (approx. 1cm) soft tissue mass is located level with the carina on both lateral views. On the R lateral recumbent view it is located ventral and, on the L lateral recumbent view it is located dorsal to the carina. On the VD view it appears to be located between ribs 6 and 7 on the left side.

SEX

Spayed Female

The cranial mediastinum is of physiological size and opacity. Air is present in the cranial thoracic esophagus and the entire, visible, GIT.

AGE

15 Year 1 Month

The cardiac silhouette appears physiological.

RADIOGRAPHIC DIAGNOSIS

INTERPRETED BY

- Mass in left cranial lung lobe
- Overinflation of lungs
- Aerophagia

Heike Rudolf, DVM,
Dr. med. Vet.,
DipECVDI DVR

INTERPRETATION OF THE FINDINGS & FURTHER RECOMMENDATIONS

The mass could represent a primary lung tumor (e.g. adenocarcinoma) or a granuloma; however, in association with the weight loss, a malignancy is more likely. The mass appears to compress bronchi. The lung expansion suggests feline asthma. Tracheo-bronchoscopy and BAL are necessary for diagnosis and treatment of pulmonary infiltrate. A CT examination will help identify small metastases and outline the mass more accurately.

HOSPITAL NAME

Blairstown AH

REFERRING VET

Dr. Zeliff

INVOICE

17164

DATE

9/2/22



PATIENT

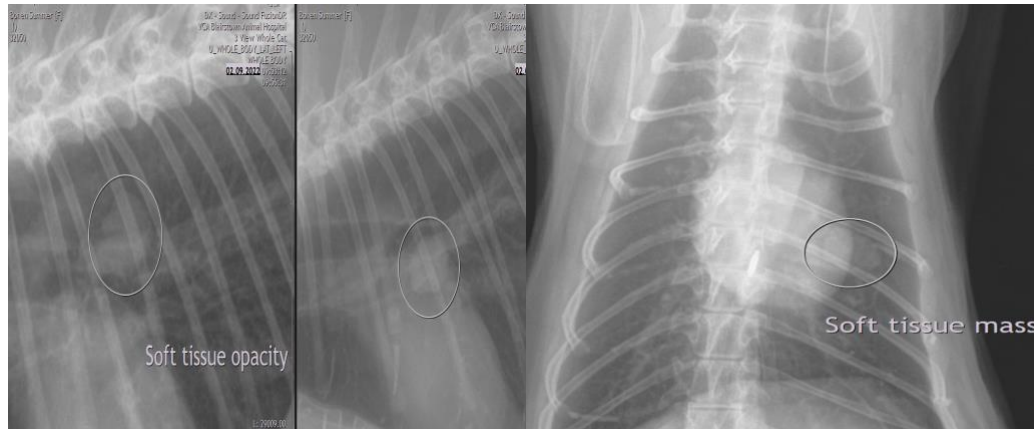
Summer Bohen

SPECIES

Feline

BREED

DSH



SEX

Spayed Female

AGE

15 Year 1 Month

The information and recommendations provided are based on the images presented by the referring veterinarian/sonographer. No evaluation can be communicated regarding pathology that was not visible in the image/video clips provided.

Thank you for this referral. If the clinical or image interpretation does not parallel your findings or if I can be of any further assistance please contact me.

Heike Rudorf, DVM, Dr. med. vet., DipECVDI, DVR
dr.h.rudorf@gmail.com

INTERPRETED BY

Heike Rudorf, DVM,
Dr. med. Vet.,
DipECVDI DVR

HOSPITAL NAME

Blairstown AH

REFERRING VET

Dr. Zeliff

INVOICE

17164

DATE

9/2/22