



PATIENT PRESENTING CLINICAL SIGNS

Max Ashmore History: Coughing this morning then passed out. No heart murmur, PE normal, temp normal. Chronic bronchitis?

SPECIES RADIOGRAPHIC STUDY OF THE THORAX

Canine The body condition score is 8/9 with smooth alternating layers of fat and soft tissue opacity.
The bony structures appear physiological.

BREED The lungs are in contact with the thoracic boundaries and the tips are pointed. The lobar vessels are clearly visible to the tertiary branches.

Westie X The cranial mediastinum is of physiological size and opacity. In left lateral recumbency the trachea between C4 and C7 is approx. 0.5cm wider than the rest. A soft tissue opacity is superimposed or extends into the tracheal lumen and appears to decrease the air shadow at this level. In right lateral recumbency the entire cervical trachea is wide and its opacity increased.

SEX

Neutered Male The cardiac silhouette occupies 75% of the chest height and 3 intercostal spaces. No chamber or outflow tract enlargement is evident.

AGE RADIOGRAPHIC DIAGNOSIS

12 Years

- Variable tracheal diameter
- Tracheal collapse (likely)

INTERPRETED BY INTERPRETATION OF THE FINDINGS & FURTHER RECOMMENDATIONS

Heike Rudorf, DVM, Dr. med. Vet., DipECVDI DVR Tracheal collapse alone can be due to a weakened dorsal tracheal ligament. Tracheal in combination with bronchial collapse is usually caused by chondromalacia and is thus due to an altered cartilage development which may go unnoticed until physical circumstances (such as stress, running, excitement) or disease (e.g. pneumonia, bronchitis, L cardiac enlargement) reduces the ease of airflow. Echocardiography to assess mitral valve as well as L atrial size. Tracheo-bronchoscopy is necessary to confirm the diagnosis and to obtain a BAL. Should an underlying disease be present treatment may improve the clinical signs.

HOSPITAL NAME

Sunridge VC Obesity is known to worsen clinical signs of cough and impair lung function; weight control is strongly recommended.

REFERRING VET

TECHNICAL COMMENTS

Dr. Duncan Lead gloves in primary beam.

INVOICE

17161

DATE

9/2/22



PATIENT

Max Ashmore

SPECIES

Canine

BREED

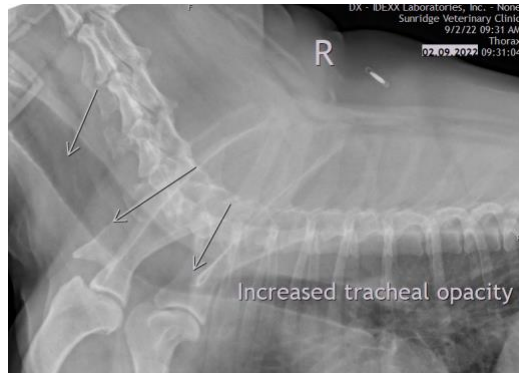
Westie X

SEX

Neutered Male

AGE

12 Years



The information and recommendations provided are based on the images presented by the referring veterinarian/sonographer. No evaluation can be communicated regarding pathology that was not visible in the image/video clips provided.

Thank you for this referral. If the clinical or image interpretation does not parallel your findings or if I can be of any further assistance please contact me.

Heike Rudorf, DVM, Dr. med. vet., DipECVDI, DVR
dr.h.rudorf@gmail.com

INTERPRETED BY

Heike Rudorf, DVM,
Dr. med. Vet.,
DipECVDI DVR

HOSPITAL NAME

Sunridge VC

REFERRING VET

Dr. Duncan

INVOICE

17161

DATE

9/2/22