



PATIENT PRESENTING CLINICAL SIGNS

Fiona Greenbaum History: History of adenocarcinoma (mammary gland) Hacking cough

RADIOGRAPHIC STUDY OF THE THORAX

SPECIES

Canine

A calcified mass is located in the subcutaneous tissue ventro-caudal to the xiphisternum. Another one is superimposed onto the fat surrounding the tail of the spleen.

The bony structures appear physiological.

BREED

Beagle

Multiple nodular opacities are present in all lung fields, ranging from 0.6 to 3cm.

The cranial mediastinum is of physiological size and opacity. The trachea diverges from the thoracic vertebrae and dips strongly at the carina. The main stem bronchi appear narrow.

SEX

Spayed Female

The cardiac silhouette occupies 75% of the chest height and 3 intercostal spaces. No chamber or outflow tract enlargement is evident.

RADIOGRAPHIC DIAGNOSIS

AGE

8 Years

- Pulmonary metastases
- Mammary tumours
- Possible hila lymphadenopathy

INTERPRETATION OF THE FINDINGS & FURTHER RECOMMENDATIONS

INTERPRETED BY

Heike Rudolf, DVM,
Dr. med. Vet.,
DipECVDI DVR

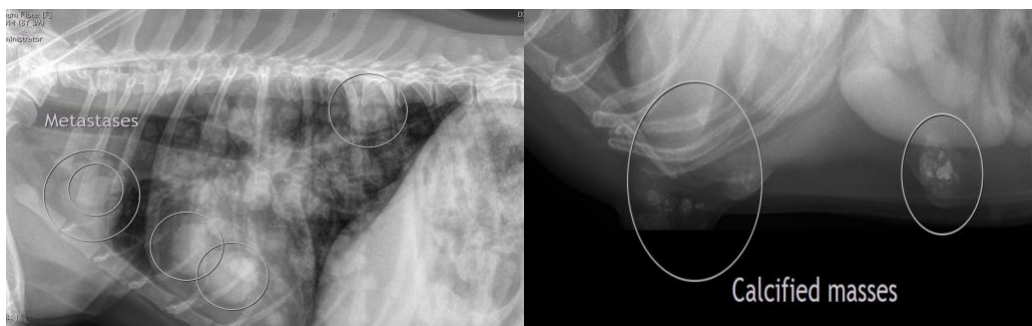
The metastases are most likely secondary to the known mammary adenocarcinoma. Differential diagnoses for the mammary masses with calcification are adenocarcinoma and adenoma. The small bronchi and acute tracheal dip at the carina suggests lymph node enlargement.

HOSPITAL NAME

New Bridge VP

REFERRING VET

Dr. Abina Glennon



The information and recommendations provided are based on the images presented by the referring veterinarian/sonographer. No evaluation can be communicated regarding pathology that was not visible in the image/video clips provided.

INVOICE

17158

Thank you for this referral. If the clinical or image interpretation does not parallel your findings or if I can be of any further assistance please contact me.

DATE

9/2/22



PATIENT

Heike Rudolf, DVM, Dr. med. vet., DipECVDI, DVR
dr.h.rudorf@gmail.com

Fiona Greenbaum

SPECIES

Canine

BREED

Beagle

SEX

Spayed Female

AGE

8 Years

INTERPRETED BY

Heike Rudolf, DVM,
Dr. med. Vet.,
DipECVDI DVR

HOSPITAL NAME

New Bridge VP

REFERRING VET

Dr. Abina Glennon

INVOICE

17158

DATE

9/2/22