



**PATIENT PRESENTING CLINICAL SIGNS**

Chica Laczynski History: Acute harsh crackly lung sounds, P has history of CKD, otherwise doing fine  
Abnormal PE/Chem/CBC/UA Results:

**SPECIES RADIOGRAPHIC STUDY OF THE THORAX**

Canine The body condition score is 7/9 with smooth alternating layers of fat and soft tissue opacity.

**BREED** The bones are well mineralized with good trabecular structure and smooth surfaces. The disc spaces appear homogeneous in width.

Chihuahua The lungs are in contact with the thoracic boundaries and the tips are pointed. The lobar vessels are poorly delineated and the bronchi are highlighted. Bronchial calcification is present. The right cranial lobar bronchus is wide, with slightly undulating surfaces. It branches abruptly without tapering.

**SEX**

Spayed Female The cranial mediastinum is of physiological size and opacity. The trachea runs parallel to the thoracic vertebrae and dips at the carina. Calcification of the tracheal rings is present.

**AGE**

14 Years

The cardiac silhouette occupies 75% of the chest height and 2.5 intercostal spaces (VHS 10). No chamber or outflow tract enlargement is evident. The region of the R atrium appears prominent.

**RADIOGRAPHIC DIAGNOSIS**

- Broncho-interstitial pattern
- Bronchiectasis

**INTERPRETED BY**

Heike Rudolf, DVM,  
Dr. med. Vet.,  
DipECVDI DVR

**INTERPRETATION OF THE FINDINGS & FURTHER RECOMMENDATIONS**

Bronchiectasis is a sign of chronic lung disease and usually associated with a general bronchial enhancement indicating bronchitis. Primary inflammatory, non-infectious causes (e.g. neutrophilic, eosinophilic, allergic), as well as infectious causes (bacterial, viral, parasitic) need to be considered.

**HOSPITAL NAME**

Boca Park AH

Interstitial fibrosis may be present. Bronchoscopy including BAL is necessary for a definitive diagnosis. The cardiac shape suggests right sided enlargement thus echocardiography is recommended to identify a Cor pulmonale and tricuspid regurgitation as an indicator for pulmonary hypertension.

**REFERRING VET**

Laura Warren

Tracheal collapse is not visible on these views but may still be present when physical circumstances (such as stress, running, excitement) or disease (e.g. pneumonia, bronchitis, left cardiac enlargement) reduces the ease of airflow. Trachea and bronchi can be assessed during the process of BAL.

**INVOICE**

12946

Obesity is known to worsen clinical signs of cough and impair lung function; weight control is recommended.

**DATE**

9/2/21



**PATIENT**

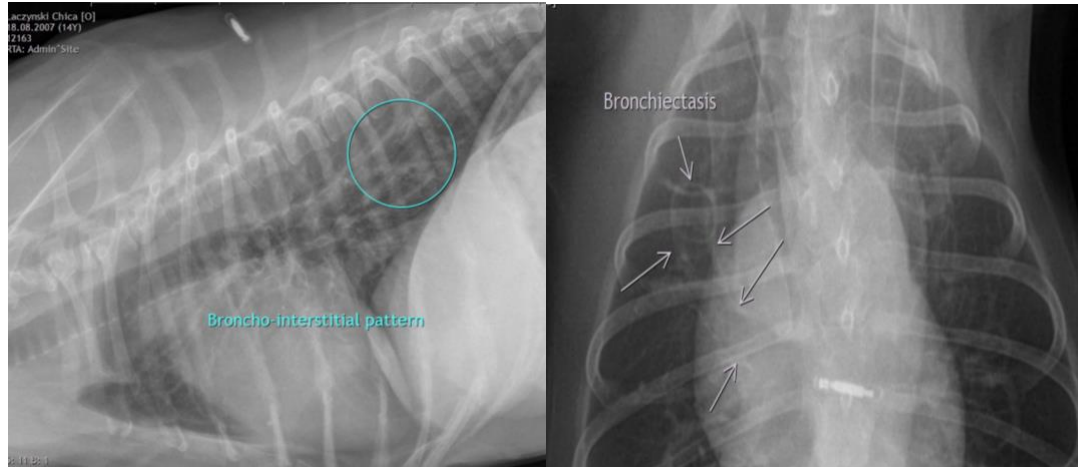
Chica Laczynski

**SPECIES**

Canine

**BREED**

Chihuahua



**SEX**

Spayed Female

The information and recommendations provided are based on the images presented by the referring veterinarian. No evaluation can be communicated regarding pathology that was not visible in the image/video clips provided.

**AGE**

14 Years

Thank you for this referral. If the clinical or image interpretation does not parallel your findings or if I can be of any further assistance please contact me.

**Heike Rudolf**, DVM, Dr. med. vet., DipECVDI, DVR  
dr.h.rudorf@gmail.com

**INTERPRETED BY**

Heike Rudolf, DVM,  
Dr. med. Vet.,  
DipECVDI DVR

**HOSPITAL NAME**

Boca Park AH

**REFERRING VET**

Laura Warren

**INVOICE**

12946

**DATE**

9/2/21