



#### PATIENT

Cricket Farrant

#### PRESENTING CLINICAL SIGNS

History: Shifting pelvic limb lameness, left worse than right.  
Abnormal PE/Chem/CBC/UA Results:

#### SPECIES

Canine

The lateral thigh muscles on the left appear slightly smaller than on the right.

Age related skeletal immaturity is noted. The skeletal structures are well mineralized, with physiological cortico-medullary development and differentiation.

#### BREED

Chihuahua Mix

The hip joints appear congruent with even subchondral bone surfaces. No new bone formation is evident. The angle of both femoral necks is steep.

#### SEX

Spayed Female

Both stifle joints have smooth subchondral bone surfaces and the centre of the femoral condyles is in line with the intercondylar eminence. The cranial fat pad has a physiological size and the caudal fascial plains are in a physiological position. New bone formation is not evident and the right patella is located in its groove.

#### AGE

11 Months

The left patella is superimposed onto the medial condyle. The tibial crest is located slightly proximal to the tibial plateau on the lateral view and the growth plate is highlighted as an irregular periosteal outline on the medial aspect. The left femur and tibia produce a genu varum.

#### INTERPRETED BY

Heike Rudolf, DVM,  
Dr. med. Vet.,  
DipECVDDI DVR

#### RADIOGRAPHIC DIAGNOSIS

- Luxating patella, left
- Genu varum, left

#### INTERPRETATION OF THE FINDINGS & FURTHER RECOMMENDATIONS

#### HOSPITAL NAME

Tahoe Integrative VC

Palpatory examination of both patellae is recommended.

The apparent genu varum may represent an artefact due to an inability to extend the leg fully. A single cranio-caudal view, centered and positioned for the left stifle joint, can help rule out an angular limb deformity.

#### REFERRING VET

Dr. Amanda Stuart

#### INVOICE

13105

#### DATE

9/15/21



**PATIENT**

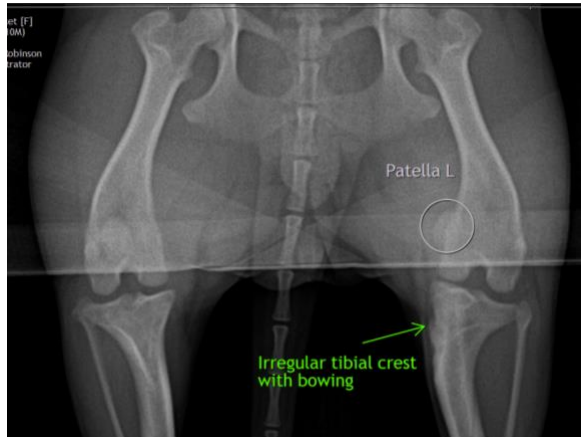
Cricket Farrant

**SPECIES**

Canine

**BREED**

Chihuahua Mix



**SEX**

Spayed Female

**AGE**

11 Months

The information and recommendations provided are based on the images presented by the referring veterinarian. No evaluation can be communicated regarding pathology that was not visible in the image/video clips provided.

Thank you for this referral. If the clinical or image interpretation does not parallel your findings or if I can be of any further assistance please contact me.

Heike Rudolf, DVM, Dr. med. vet., DipECVDI, DVR  
dr.h.rudorf@gmail.com

**INTERPRETED BY**

Heike Rudolf, DVM,  
Dr. med. Vet.,  
DipECVDI DVR

**HOSPITAL NAME**

Tahoe Integrative VC

**REFERRING VET**

Dr. Amanda Stuart

**INVOICE**

13105

**DATE**

9/15/21