



PATIENT PRESENTING CLINICAL SIGNS

Calico Roque History: Chief Complaint: sneezing History: p began sneezing 2 weeks ago, yellow discharge from nose, o noted a growth on head a week ago and noticed it growing.

SPECIES Abnormal PE/Chem/CBC/UA Results: CV/Respiratory: Normal heart rate and rhythm, no murmur, pulses strong and synchronous, normal bronchovesicular sounds. EENT: Clear OU. AU: mild black debris, multiple ceruminous cysts. No nasal discharge, but sounds congested. No cough on tracheal palpation. **** Irregular shape, firm soft tissue growth on larynx area bilaterally **** - see photos attached
Feline
BREED Oral cavity: Moderate dental tartar and mild to moderate gingivitis. Musculoskeletal: BCS = 5/9. Ambulatory x 4 Uro/Perineum: No significant lesions Abd/GI: Soft, non-painful. No masses or fluid wave palpated Lymph Nodes: No peripheral lymphadenopathy Neurological: Alert and appropriate. No significant abnormalities Skin: ~1cm semi-firm swelling with SQ emphysema between eyes. Good hair coat. No ectoparasites seen Mentation: BAR Hydration: N 1) CBC: WBC 19.71 (2.87-17.02), NEU 13.93 (2.30-10.29), MONO 1.10 (0.05-0.67) 2) CHEM: GLOB 5.6 (2.8-5.1)

SEX RADIOGRAPHIC STUDY OF THE HEAD

Spayed Female Both nostrils contain air.

AGE Caudally to the canine tooth one nasal chamber shows an increased opacity. On the lateral oblique view the more dorsally located maxillary bone appear to have a 0.8cm long gap and the bones on either side appear thinner. A soft tissue swelling dorsal to the bone defect contains gas.

9 Years 6 Months

RADIOGRAPHIC DIAGNOSIS

- INTERPRETED BY**
- Gas filled soft tissue swelling
 - Bone destruction

Heike Rudolf, DVM,
 Dr. med. Vet.,
 DipECVDDI DVR

INTERPRETATION OF THE FINDINGS & FURTHER RECOMMENDATIONS

The changes could be due to an abscess with gas forming organisms or represent a tumor connected to the airways. The increased opacity in one nasal chamber may be due to the superimposed soft tissue swelling or could represent a nasal tumour. A CT examination is recommended and the lymph nodes should be included.

HOSPITAL NAME

DPC Veterinary H

TECHNICAL COMMENTS

REFERRING VET

No side markers

Dr. Rivera

INVOICE

13104

DATE

9/15/21



PATIENT

Calico Roque

SPECIES

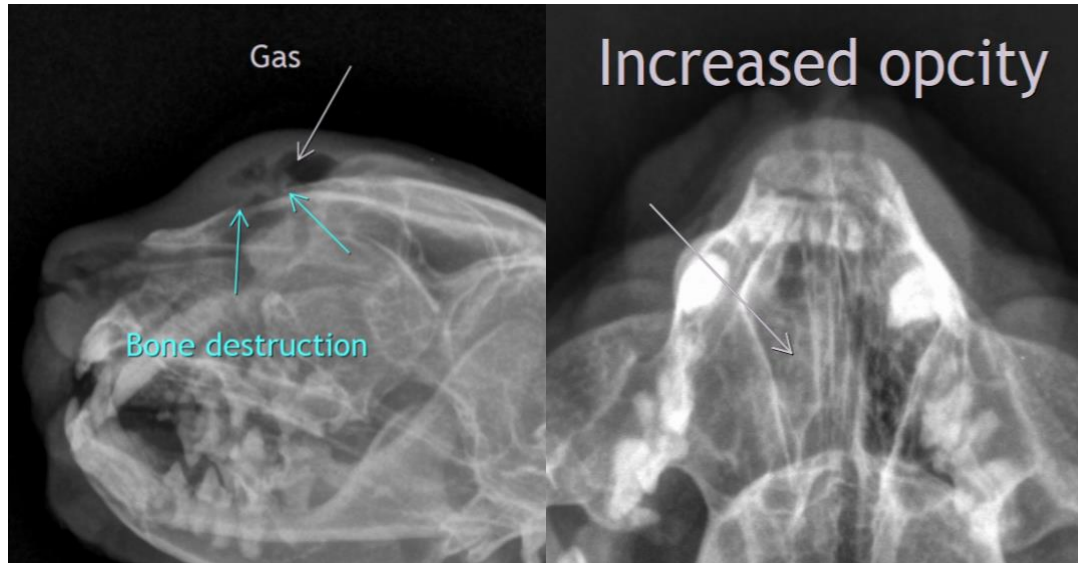
Feline

BREED

DSH

SEX

Spayed Female



AGE

9 Years 6 Months

The information and recommendations provided are based on the images presented by the referring veterinarian. No evaluation can be communicated regarding pathology that was not visible in the image/video clips provided.

INTERPRETED BY

Heike Rudolf, DVM,
Dr. med. Vet.,
DipECVDDI DVR

Thank you for this referral. If the clinical or image interpretation does not parallel your findings or if I can be of any further assistance please contact me.

Heike Rudolf, DVM, Dr. med. vet., DipECVDDI, DVR
dr.h.rudorf@gmail.com

HOSPITAL NAME

DPC Veterinary H

REFERRING VET

Dr. Rivera

INVOICE

13104

DATE

9/15/21