



PATIENT PRESENTING CLINICAL SIGNS

Beatrice Jarit History: Puppy count. P is due in a week.

RADIOGRAPHIC STUDY OF THE ABDOMEN

SPECIES Rib 13 on the right is thick, on the left it is barely visible.

Canine A large amount of formed feces is present in colon and rectum.

BREED I can see four heads and four vertebral columns.

Shetland Sheepdog

RADIOGRAPHIC DIAGNOSIS

- Four puppies have been identified
- Congenital rib anomaly (incidental finding)

SEX

Female

INTERPRETATION OF THE FINDINGS & FURTHER RECOMMENDATIONS

I can see four fetuses on the lateral view.

AGE

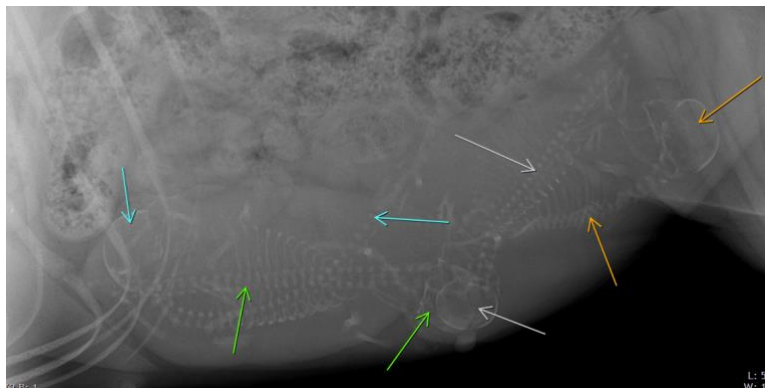
1 Year 10 Months

INTERPRETED BY

Heike Rudolf, DVM,
Dr. med. Vet.,
DipECVDI DVR

HOSPITAL NAME

The Pet Hospital of
Stratford



The information and recommendations provided are based on the images presented by the referring veterinarian/sonographer. No evaluation can be communicated regarding pathology that was not visible in the image/video clips provided.

REFERRING VET

Dr. Caroline David

Thank you for this referral. If the clinical or image interpretation does not parallel your findings or if I can be of any further assistance please contact me.

Heike Rudolf, DVM, Dr. med. vet., DipECVDI, DVR
dr.h.rudorf@gmail.com

INVOICE

17302

DATE

9/13/22



PATIENT

Beatrice Jarit

SPECIES

Canine

BREED

Shetland Sheepdog

SEX

Female

AGE

1 Year 10 Months

INTERPRETED BY

Heike Rudorf, DVM,
Dr. med. Vet.,
DipECVDI DVR

HOSPITAL NAME

The Pet Hospital of
Stratford

REFERRING VET

Dr. Caroline David

INVOICE

17302

DATE

9/13/22