

**PATIENT**

Winnie Bellucci

PRESENTING CLINICAL SIGNS

History: II/VI murmur. Cough and nasal congestion. Recent hyperthyroid diagnosis. Heartworm test pending.

SPECIES

Feline

Abnormal PE/Chem/CBC/UA Results: Hyperthyroid

RADIOGRAPHIC STUDY OF THE THORAX**BREED**

DSH

The body condition score is 7/9 with smooth alternating layers of fat and soft tissue opacity.

SEX

Spayed Female

The caudal sternum is dorsally displaced.

The lungs are in contact with the thoracic boundaries and the tips are pointed. The lobar vessels are clearly visible; the main vessels for the caudal lobes are slightly larger than rib 9 at the intersection with the rib but the cranial lobar vessels are of physiological size. A mild, centrally located peribronchial infiltrate has resulted in the formation of some doughnuts.

AGE

11 Years

The cranial mediastinum is of physiological size and opacity. The trachea diverges from the thoracic vertebrae and the carina is located at T5.

The cardiac silhouette occupies 75% of the chest height and 2.5 intercostal spaces; increased sternal contact is due to the cardiac position. No chamber or outflow tract enlargement is evident.

RADIOGRAPHIC DIAGNOSIS**INTERPRETED BY**

Heike Rudorf, DVM,
Dr. med. Vet.,
DipECVDI DVR

- Mild peribronchial infiltrate
- Congenital sternal anomaly

INTERPRETATION OF THE FINDINGS & FURTHER RECOMMENDATIONS**HOSPITAL NAME**

Four Corners VP

An absence of radiographic cardiac enlargement does not preclude HCM as it results in concentric muscular enlargement. This is best detected ultrasonographically; regurgitant jets will also be appreciable. The few doughnuts are likely the result of a previous bronchitis but may also be caused by current inflammation, infection or interstitial edema due to HCM. Tracheo-bronchoscopy would be needed to obtain a sample for bacteriology and cytology.

REFERRING VET

Gregory Roccaro

Obesity is a known to worsen clinical signs of cough and impair lung function; weight control is strongly recommended.

INVOICE

12941

DATE

9/1/21



PATIENT

Winnie Bellucci

SPECIES

Feline

BREED

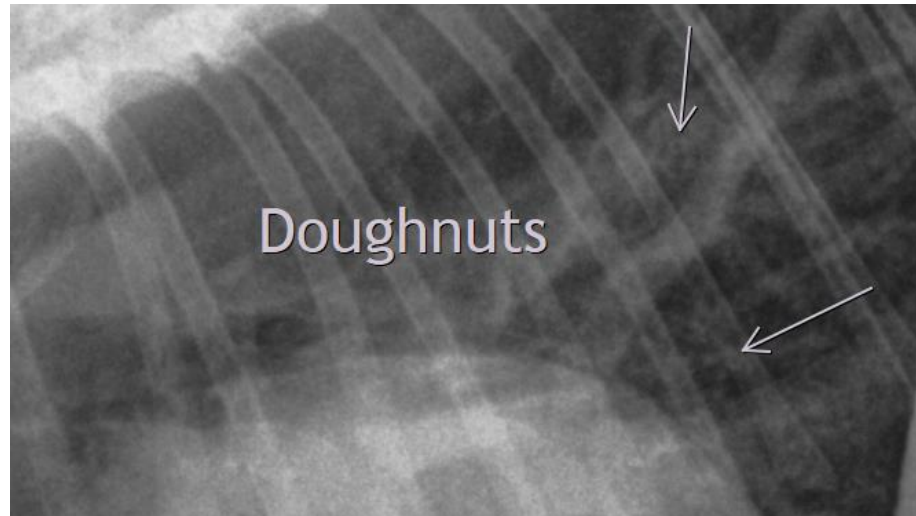
DSH

SEX

Spayed Female

AGE

11 Years



The information and recommendations provided are based on the images presented by the referring veterinarian. No evaluation can be communicated regarding pathology that was not visible in the image/video clips provided.

Thank you for this referral. If the clinical or image interpretation does not parallel your findings or if I can be of any further assistance please contact me.

Heike Rudolf, DVM, Dr. med. vet., DipECVDI, DVR
dr.h.rudorf@gmail.com

INTERPRETED BY

Heike Rudolf, DVM,
Dr. med. Vet.,
DipECVDI DVR

HOSPITAL NAME

Four Corners VP

REFERRING VET

Gregory Roccaro

INVOICE

12941

DATE

9/1/21