



PATIENT	PRESENTING CLINICAL SIGNS
Emma Fasanella	O reports heavy breathing/panting at night while sleeping, o shared video. MM: pink, no resp distress on PE, no murmur detected. Noted collapsing trachea thoracic inlet on rads and mineralization L kidney.
SPECIES	Abnormal PE/Chem/CBC/UA Results: Hypothyroidism tx, Low B-12 tx
Canine	RADIOGRAPHIC STUDY OF THORAX AND ABDOMEN
	LLR and VD dogogram
BREED	RADIOGRAPHIC FINDINGS
Dauschund	The body condition score is 6/9 with a large amount of subcutaneous fat dorsal to the lumbar spine.
SEX	New one formation is present in both elbow and one shoulder joint. The dorso-ventral dimension of the thoracic cavity is reduced, resulting in the impression of cardiomegaly.
FS	<u>Thorax</u>
AGE	The lungs are in contact with the thoracic boundaries and the tips are pointed. The lobar vessels are clearly visible to the tertiary branches. The visible bronchial tree is thin walled and tapers uniformly towards the periphery.
15 Years	The cranial mediastinum is of physiological size and opacity. The tracheal diameter varies markedly and between C4 and T3 a soft tissue structure extends into the lumen from dorsally and reduces the air space to a minimum of approx. 0.3cm. The trachea is in close contact to the vertebrae and narrows just cranial to the carina which is in line with the trachea.
INTERPRETED BY	
Heike Rudolf, DVM, Dr. med. Vet., DipECVDI DVR	
HOSPITAL NAME	The cardiac silhouette occupies 90% of the chest height and 3 intercostal spaces (VHS 9). No chamber or outflow tract enlargement is evident.
Healing Paws	<u>Abdomen</u>
REFERRING VET	The abdominal detail is in line with the BCS; diaphragm and abdominal wall are intact.
Stephanie Chabalko, DVM	The liver is located within the costal arch and the caudo-ventral lobe is pointed.
	The spleen appears physiological.
INVOICE	The stomach contains a large amount of air and some food, the air continues into the duodenum where the walls appear prominent. The small intestinal loops occupy the central abdomen and vary slightly in height. Colon and rectum are virtually empty.
47306	Mineralization is present in the L renal pelvis. The urinary bladder neck is located in the pelvic canal; the organ is of homogeneous fluid opacity.
DATE	
9-1-21	The region of the sublumbar lymph nodes appears physiological.



PATIENT

Emma Fasanella

RADIOGRAPHIC DIAGNOSIS

- Tracheal collapse, severe
- Incidental findings
 - OA elbows
 - OA one shoulder
 - Renal pelvic calcification

SPECIES

Canine

BREED

Dauschund

INTERPRETATION OF THE FINDINGS & FURTHER RECOMMENDATIONS

Tracheal collapse alone can be due to a weakened dorsal tracheal ligament. Tracheal as well as tracheo-bronchial collapse is usually caused by chondromalacia and is thus due to an altered cartilage development which may go unnoticed until physical circumstances (such as stress, running, excitement) or disease (e.g. pneumonia, bronchitis, L cardiac enlargement) reduces the ease of airflow. Echocardiography to assess mitral valve and L atrial size and bronchoscopy to obtain a BAL is recommended. Should an underlying disease be present treatment may improve the clinical signs.

SEX

FS

Urea and creatinine can be checked, and a urine sample obtained, to assess renal function and identify cystitis.

AGE

15 Years

INTERPRETED BY

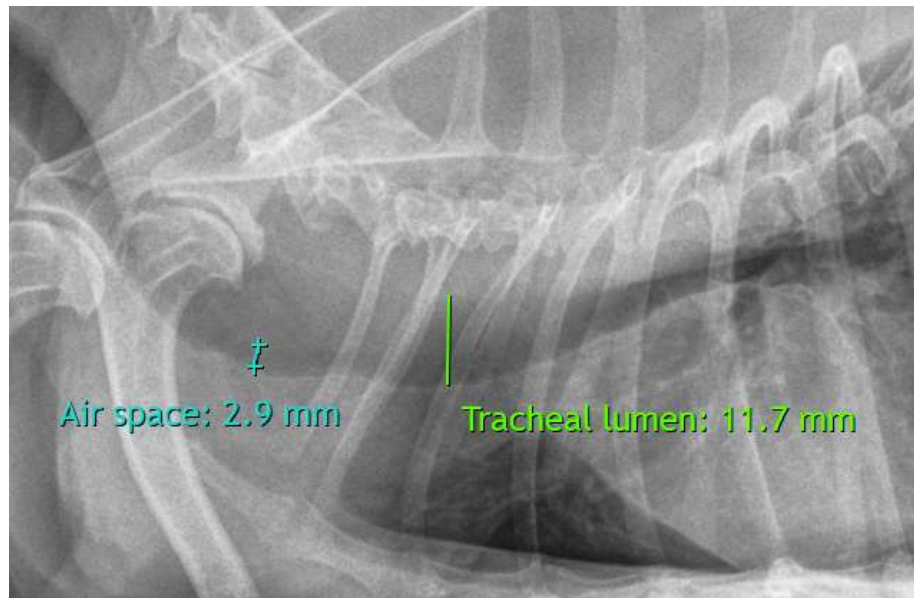
Heike Rudolf, DVM,
Dr. med. Vet.,
DipECVDI DVR

HOSPITAL NAME

Healing Paws

REFERRING VET

Stephanie Chabalko,
DVM



INVOICE

47306

DATE

9-1-21



PATIENT

Emma Fasanella

The information and recommendations provided are based on the images presented by the referring veterinarian. No evaluation can be communicated regarding pathology that was not visible in the image/video clips provided.

SPECIES

Canine

Thank you for this referral. If the clinical or image interpretation does not parallel your findings or if I can be of any further assistance please contact me.

BREED

Dauschund

Heike Rudolf, DVM, Dr. med. vet., DipECVDI, DVR
Dr.H.Rudorf@gmail.com

SEX

FS

AGE

15 Years

INTERPRETED BY

Heike Rudolf, DVM,
Dr. med. Vet.,
DipECVDI DVR

HOSPITAL NAME

Healing Paws

REFERRING VET

Stephanie Chabalko,
DVM

INVOICE

47306

DATE

9-1-21