



**PATIENT PRESENTING CLINICAL SIGNS**

Annie Docimo Coughing since 8/5/2021 was at a boarding facility 7/26/2021 had kennel cough vaccine 7/23/2021. Treated for kennel cough w/ clavamox and hycodan.

**SPECIES RADIOGRAPHIC STUDY OF THE THORAX**

Canine 2 orthogonal views

**RADIOGRAPHIC FINDINGS**

The body condition score is 7-8/9 with smooth alternating layers of fat and soft tissue opacity.

**BREED**

Cuton De Tuleare The bony structures appear physiological.

**SEX**

The lungs are in contact with the thoracic boundaries and the tips are pointed. The lobar vessels are clearly visible to the tertiary branches on the VD view. The bronchial tree is thin walled and mild bronchial wall calcification is present.

Female S

**AGE**

The cranial mediastinum is of physiological size and opacity. The trachea runs parallel to the thoracic vertebrae and dips at the carina.

7/16/2013

The cardiac silhouette occupies 80% of the chest height and 3 intercostal spaces (VHS 10). No chamber or outflow tract enlargement is evident.

**INTERPRETED BY**

**RADIOGRAPHIC DIAGNOSIS**

Heike Rudolf, DVM,  
Dr. med. Vet.,  
DipECVDDI DVR

- Bronchial mineralization
- Obesity

**HOSPITAL NAME**

**INTERPRETATION OF THE FINDINGS & FURTHER RECOMMENDATIONS**

Cottage Grove  
Veterinary Clinic

The lung pattern is, for a 7-year-old animal, not particularly abnormal. However, bronchitis can be present without radiographic evidence. Bronchoscopy including BAL is necessary for a definitive diagnosis. Primary inflammatory, non-infectious causes (e.g. neutrophilic, eosinophilic, allergic), as well as infectious causes (bacterial, viral, parasitic) need to be considered.

**REFERRING VET**

Obesity is known to worsen clinical signs of cough and impair lung function; weight control is strongly recommended.

Damewood

**TECHNICAL COMMENTS**

**INVOICE**

Lead gloves in primary beam

47304

**DATE**

9-1-21



**PATIENT**

Annie Docimo

**SPECIES**

Canine

**BREED**

Cuton De Tuleare

**SEX**

Female S

**AGE**

7/16/2013

**INTERPRETED BY**

Heike Rudolf, DVM,  
Dr. med. Vet.,  
DipECVDDI DVR

**HOSPITAL NAME**

Cottage Grove  
Veterinary Clinic

**REFERRING VET**

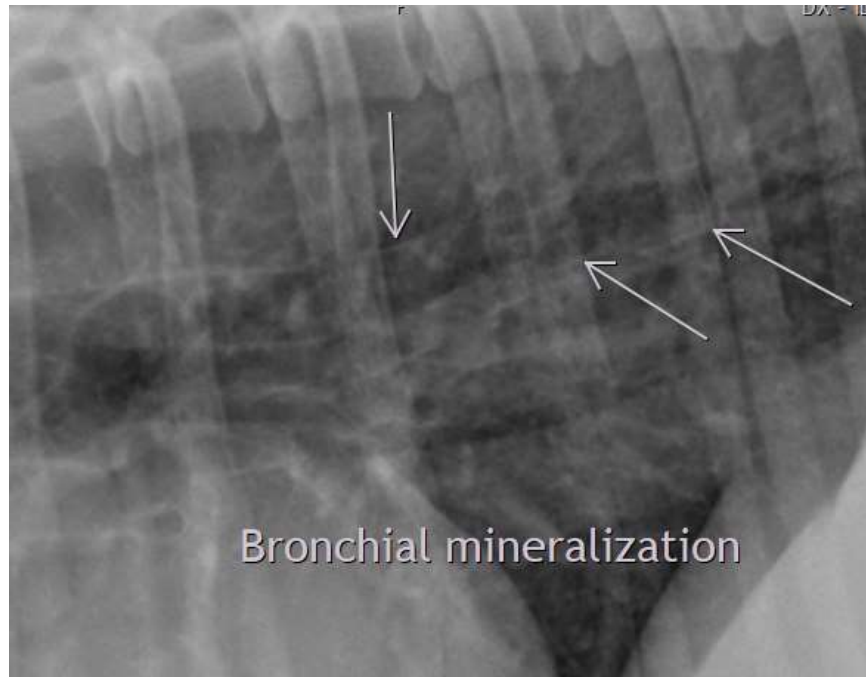
Damewood

**INVOICE**

47304

**DATE**

9-1-21



**The information and recommendations provided are based on the images presented by the referring veterinarian. No evaluation can be communicated regarding pathology that was not visible in the image/video clips provided.**

Thank you for this referral. If the clinical or image interpretation does not parallel your findings or if I can be of any further assistance please contact me.

**Heike Rudolf, DVM, Dr. med. vet., DipECVDDI, DVR**  
Dr.H.Rudorf@gmail.com