



**PATIENT PRESENTING CLINICAL SIGNS**

Cookie Lara History: P presents 4-5 days post distended abdomen. O unaware when P's last heat was - no intact males in home. No fever (100.2). P is BAR. No discharge from vulva. P ate a full meal this morning prior to radiographs.

**SPECIES RADIOGRAPHIC STUDY OF THE ABDOMEN**

Canine The body condition score is 7/9 with smooth alternating layers of fat and soft tissue opacity.

The bony structures appear physiological.

**BREED**

The ventral abdominal wall is pendulous.

Maltese

The liver extends just beyond the costal arch and the caudo-ventral lobe is rounded.

**SEX**

In right lateral recumbency an egg-shaped soft tissue mass appears to be superimposed onto the tail of the spleen.

Intact Female

The stomach contains a large amount of food; distribution and size of the small intestinal loops appear physiological. Colon and rectum contain a moderate amount of formed fecal matter.

**AGE**

Both renal shadows appear to be physiological. The bladder is located in the abdominal cavity and contains a small amount of homogeneous fluid opacity.

11 Years

The uterine body is just visible in left lateral recumbency with a height of less than 1cm.

**INTERPRETED BY** The sublumbar region appears physiological.

Heike Rudolf, DVM,  
Dr. med. Vet.,  
DipECVDI DVR

**RADIOGRAPHIC DIAGNOSIS**

- Possible splenic mass
- Hepatomegaly, mild
- Pendulous ventral abdominal wall
- Obesity, mild

**HOSPITAL NAME**

The Pet Hospital of  
Stratford

**INTERPRETATION OF THE FINDINGS & FURTHER RECOMMENDATIONS**

Abdominal ultrasound is recommended to rule out a splenic mass and to assess adrenal gland size in case Cushing's disease is the cause for the pendulous ventral abdominal wall and the mild hepatomegaly. Hepatomegaly can also be a sequel to diabetes mellitus. Full biochemistry may have to be followed by ACTH stimulation test if liver enzyme elevation in combination with a physiological glucose level is present. I do not feel that the uterine body is large but only ultrasound can tell if fluid is present in the lumen.

**REFERRING VET**

Dr. Ashley Miller

**INVOICE**

16750

**DATE**

8/5/22



**PATIENT**

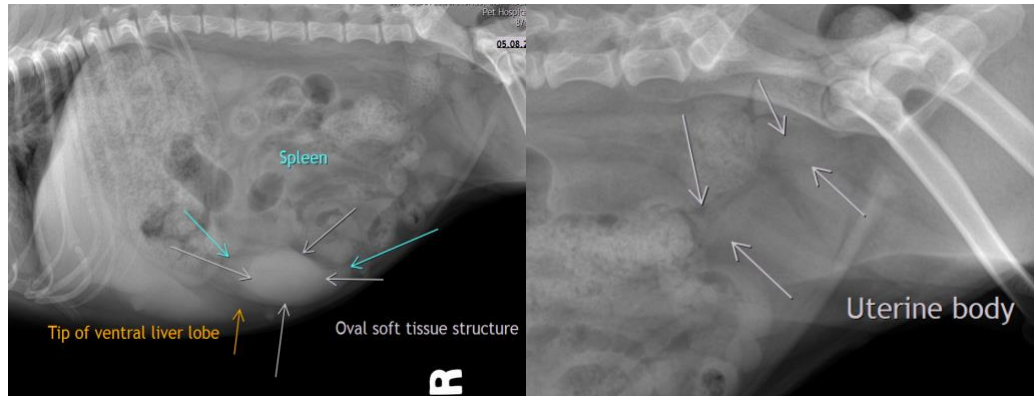
Cookie Lara

**SPECIES**

Canine

**BREED**

Maltese



**SEX**

Intact Female

**The information and recommendations provided are based on the images presented by the referring veterinarian/sonographer. No evaluation can be communicated regarding pathology that was not visible in the image/video clips provided.**

**AGE**

11 Years

Thank you for this referral. If the clinical or image interpretation does not parallel your findings or if I can be of any further assistance please contact me.

**Heike Rudorf, DVM, Dr. med. vet., DipECVDI, DVR**  
dr.h.rudorf@gmail.com

**INTERPRETED BY**

Heike Rudorf, DVM,  
Dr. med. Vet.,  
DipECVDI DVR

**HOSPITAL NAME**

The Pet Hospital of  
Stratford

**REFERRING VET**

Dr. Ashley Miller

**INVOICE**

16750

**DATE**

8/5/22