



PATIENT PRESENTING CLINICAL SIGNS

Chancho Herrera History: coughing
 Abnormal PE/Chem/CBC/UA Results: Oral cavity: Minimal dental tartar. Few Dermal/SQ masses (see previous notes). CV/Respiratory: Normal heart rate and rhythm, no murmur, pulses strong and synchronous, normal bronchovesicular sounds.

SPECIES

Canine

RADIOGRAPHIC STUDY OF THE THORAX

The body condition score is 6/9 with smooth alternating layers of fat and soft tissue opacity.

BREED

The bony structures appear physiological.

Boxer Mix

The lungs are in contact with the thoracic boundaries and the tips are pointed. The lobar vessels are clearly visible to the tertiary branches. The bronchial tree is thin walled and tapers uniformly towards the periphery.

SEX

Neutered Male

The cranial mediastinum is of physiological size and opacity. The trachea diverges from the thoracic vertebrae and dips at the carina. A soft tissue band extends into or is superimposed onto the caudal cervical trachea.

AGE

8 Years 9 Months

The cardiac silhouette occupies 75% of the chest height and 3 intercostal spaces (VHS 11). No chamber or outflow tract enlargement is evident.

RADIOGRAPHIC DIAGNOSIS

- Possible tracheal collapse

INTERPRETED BY

Heike Rudolf, DVM,
 Dr. med. Vet.,
 DipECVDI DVR

INTERPRETATION OF THE FINDINGS & FURTHER RECOMMENDATIONS

Tracheal collapse is not often present in large breed dogs and then it is usually without consequence for the dog because of the large luminal diameter. However, in brachycephalic dogs that may become clinically significant. Bronchitis can be present without radiographic evidence. Thus, bronchoscopy with broncho-alveolar lavage is necessary to rule out infection and inflammation and tracheal collapse. The vocal cords can be examined under induction to rule out laryngeal paralysis. I can see no radiographic evidence of cardiac chamber enlargement, but only echocardiography is able to rule out a beginning DCM.

HOSPITAL NAME

DPC Veterinary H

REFERRING VET

Dr. Oldenhoff

INVOICE

16749

DATE

8/5/22



PATIENT

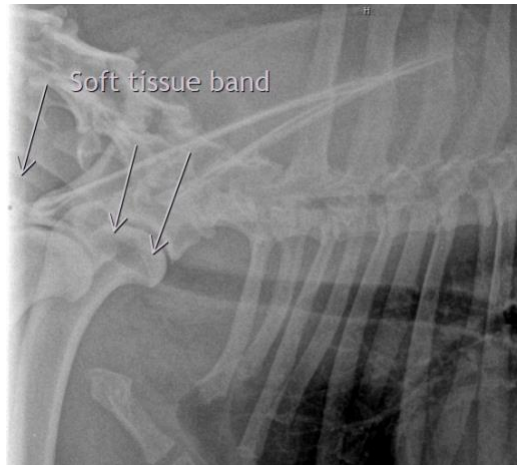
Chancho Herrera

SPECIES

Canine

BREED

Boxer Mix



SEX

Neutered Male

The information and recommendations provided are based on the images presented by the referring veterinarian/sonographer. No evaluation can be communicated regarding pathology that was not visible in the image/video clips provided.

AGE

8 Years 9 Months

Thank you for this referral. If the clinical or image interpretation does not parallel your findings or if I can be of any further assistance please contact me.

Heike Rudolf, DVM, Dr. med. vet., DipECVDI, DVR
dr.h.rudorf@gmail.com

INTERPRETED BY

Heike Rudolf, DVM,
Dr. med. Vet.,
DipECVDI DVR

HOSPITAL NAME

DPC Veterinary H

REFERRING VET

Dr. Oldenhoff

INVOICE

16749

DATE

8/5/22