



**PATIENT PRESENTING CLINICAL SIGNS**

Ace Jeeves History: Hx of anal gland adenocarcinoma. Removed several times

**RADIOGRAPHIC STUDY OF THE THORAX**

**SPECIES** The body condition score is 7/9 with smooth alternating layers of fat and soft tissue opacity.

Canine A moderate amount of smooth new bone is located on some ventral end plates.

At least four nodular structures of approx. 4.0 cm diameter are present in the lungs.

**BREED** The cranial mediastinum appears physiological.

Lab The cardiac silhouette occupies 75% of the chest height and 2.5 intercostal spaces. No chamber or outflow tract enlargement is evident.

**SEX RADIOGRAPHIC DIAGNOSIS**

Neutered Male
 

- Pulmonary metastases
- Spondylosis (incidental finding)

**AGE INTERPRETATION OF THE FINDINGS & FURTHER RECOMMENDATIONS**

10 The size of the metastases indicates a long-standing problem unless they are growing very fast. Due to the position of the fore legs I cannot assess the sternal lymph nodes, which may be enlarged as well. The chain of sublumbar lymph nodes and the sternal nodes can be assessed ultrasonographically. To evaluate size and number of the metastases, further thoracic radiographs can be obtained when respiratory signs occur.

**INTERPRETED BY**

Heike Rudolf, DVM,  
Dr. med. Vet.,  
DipECVDI DVR

**HOSPITAL NAME**

Bayshore VH

**REFERRING VET**

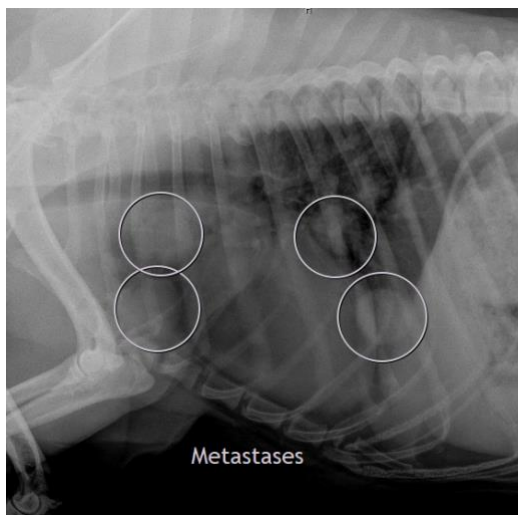
Dr. Hunt

**INVOICE**

16746

**DATE**

8/5/22





**PATIENT** The information and recommendations provided are based on the images presented by the referring veterinarian/sonographer. No evaluation can be communicated regarding pathology that was not visible in the image/video clips provided.

Ace Jeeves

Thank you for this referral. If the clinical or image interpretation does not parallel your findings or if I can be of any further assistance please contact me.

**SPECIES**

Canine **Heike Rudolf**, DVM, Dr. med. vet., DipECVDI, DVR  
dr.h.rudorf@gmail.com

**BREED**

Lab

**SEX**

Neutered Male

**AGE**

10

**INTERPRETED BY**

Heike Rudolf, DVM,  
Dr. med. Vet.,  
DipECVDI DVR

**HOSPITAL NAME**

Bayshore VH

**REFERRING VET**

Dr. Hunt

**INVOICE**

16746

**DATE**

8/5/22