



**PATIENT PRESENTING CLINICAL SIGNS**

**Coco Hinds** History: Hypothyroid, on meds. At the kennel for 2 weeks. Coughing started when returned home. Tx initially with Doxycycline. No improvement, appetite reduced. X-rays taken. Changed antibiotics to Baytril. Still not improving. Lethargic, not eating, no fever.

**SPECIES** Abnormal PE/Chem/CBC/UA Results: No other testing done

**Canine RADIOGRAPHIC STUDY OF THE THORAX**

The body condition score is 5/9 with smooth alternating layers of fat and soft tissue opacity.

**BREED** Sternebra 6 is short. Strong, homogeneous calcification is present on multiple costo-chondral junctions.

**Labrador Retriever** The degree of pulmonary expansion is good. The lungs are in contact with the thoracic boundaries and the tips are pointed. The tertiary lobar vessels are blurred, peripheral bronchi are highlighted. Areas of alveolar infiltrate surround some of the peripheral bronchi, e.g. the cranio-ventral lobes. The bronchial walls are calcified.

**SEX**

**Spayed Female** The cranial mediastinum is of physiological size and opacity. The trachea diverges from the thoracic vertebrae.

**AGE** The cardiac silhouette occupies 75% of the chest height and 2.5 intercostal spaces. No chamber or outflow tract enlargement is evident.

11

**RADIOGRAPHIC DIAGNOSIS**

- Mixed lung infiltrate

**INTERPRETED BY**

Incidental findings

Heike Rudorf, DVM,  
Dr. med. Vet.,  
DipECVDI DVR

- Congenital sternal anomaly
- Bulbous calcification at costo-chondral junctions

**HOSPITAL NAME INTERPRETATION OF THE FINDINGS & FURTHER RECOMMENDATIONS**

**Windermere VH** A mixed lung pattern can be due to infection (viral, bacterial, fungal, parasitic) or inflammation (eosinophilic broncho-pneumopathy). Tracheo-bronchoscopy is necessary to obtain a broncho-alveolar lavage. Lung worm can be ruled out with a fecal sample. The larynx should be assessed for paralysis prior to intubation in case laryngeal paralysis is present which can lead to aspiration pneumonia. Blood for hematology and biochemistry should be obtained if it has not already been done.

**REFERRING VET**

Dr. Dana Madsen

**INVOICE**

23785

**DATE**

8/4/23



**PATIENT**

Coco Hinds

**SPECIES**

Canine

**BREED**

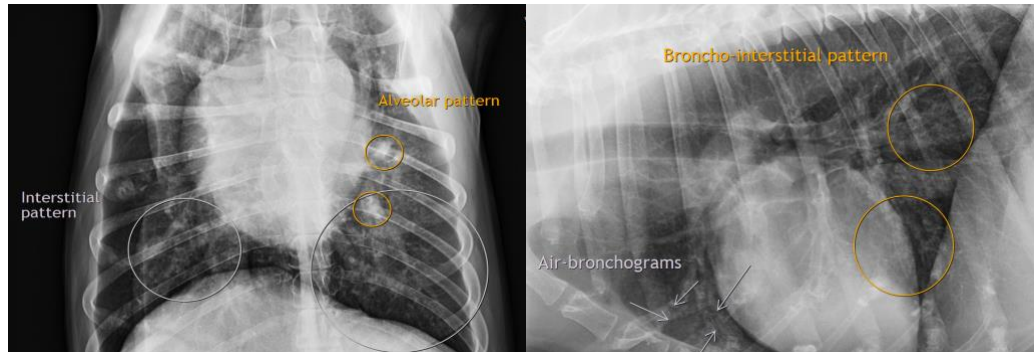
Labrador Retriever

**SEX**

Spayed Female

**AGE**

11



**The information and recommendations provided are based on the images presented by the referring veterinarian/sonographer. No evaluation can be communicated regarding pathology that was not visible in the image/video clips provided.**

Thank you for this referral. If the clinical or image interpretation does not parallel your findings or if I can be of any further assistance please contact me.

**Heike Rudolf**, DVM, Dr. med. vet., DipECVDI, DVR  
info@sonopath.com

**INTERPRETED BY**

Heike Rudolf, DVM,  
Dr. med. Vet.,  
DipECVDI DVR

**HOSPITAL NAME**

Windermere VH

**REFERRING VET**

Dr. Dana Madsen

**INVOICE**

23785

**DATE**

8/4/23