



PATIENT PRESENTING CLINICAL SIGNS

Belle Spawn Cull Fournier
 History: Not acting like herself for about 2 weeks. Not as active and not as social, cranky. Exam findings borderline dehydration and constipation, rest WNL. Attitude improved some following SQ fluid administration and dose of buprinex.

SPECIES Abnormal PE/Chem/CBC/UA Results: urine showed hematuria, bloodwork showed mild increase to proBNP (121 pmol/L) rest WNL
 Feline

RADIOGRAPHIC STUDY OF THORAX AND ABDOMEN

BREED

DLH
 The body condition score is 6/9 with smooth alternating layers of fat and soft tissue opacity.

The left hip joint appears to contain two bone fragments, one in the region of the teres ligament and another one level with the caudal acetabular edge. This is only visible on the straight VD view.

SEX

Spayed Female

Thorax

The lungs are in contact with the thoracic boundaries and the tips are pointed. The cranial lobes extend cranially beyond the first rib and the gap between heart and diaphragm is increased. The lobar vessels are clearly visible and the visible bronchial tree is thin walled, tapering uniformly towards the periphery.

AGE

13 Years

The cranial mediastinum is of physiological size and opacity. The trachea diverges from the thoracic vertebrae and the carina is located at T5.

INTERPRETED BY

Heike Rudorf, DVM, Dr. med. Vet., DipECVDI DVR
 The cardiac silhouette occupies 75% of the chest height and 2 intercostal spaces. No chamber or outflow tract enlargement is evident.

Abdomen

HOSPITAL NAME

Blandford AH

The abdominal detail is good; diaphragm and abdominal wall are intact.

The liver is located within the costal arch and the caudo-ventral lobe is pointed.

REFERRING VET

Amber Cull-Fournier

The spleen appears physiological though on the VD image with the descending colon in the midline, the region of the head of the spleen is slightly indistinct.

The stomach contains a moderate amount of food; the small intestinal loops occupy the centro-ventral abdomen and appear of homogeneous and physiological size. Colon and rectum contain gas and a moderate amount of fecal matter.

INVOICE

12916

DATE

8/31/21



PATIENT Belle Spawn Cull Fournier

Both renal shadows have a physiological size and opacity; the visible surfaces appear smooth. The bladder is located in the abdominal cavity and contains a homogeneous fluid opacity; it is compressed from dorsally by the descending colon.

The region of the sublumbar lymph nodes appears physiological.

SPECIES RADIOPHIC DIAGNOSIS

- Feline
 - Overexpansion of lungs, mild
 - Possible OA left hip joint
 - Indistinct splenic shadow (one view only)

BREED

DLH INTERPRETATION OF THE FINDINGS & FURTHER RECOMMENDATIONS

SEX Spayed Female

The mild overexpansion of the lung in both views suggests air trapping as is seen with feline asthma. Peribronchial infiltrate may be present but not radiographically apparent. Bronchoscopy and broncho-alveolar lavage are suggested.

AGE 13 Years

The changes in the left hip may be significant as they may be causing pain; thus, obtaining a VD with extended legs, centered and exposed for the pelvis is recommended. The indistinct splenic shadow is only apparent on one view and thus probably represents an artefact. However, pancreatic disease and localized peritonitis should be ruled out ultrasonographically; this will also permit looking at the urinary tract to rule out infection or tumor.

INTERPRETED BY

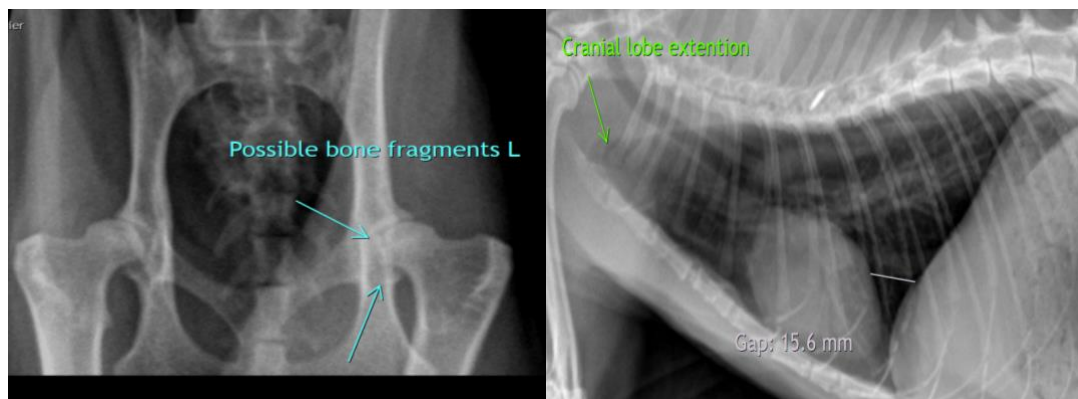
Heike Rudolf, DVM, Dr. med. Vet., DipECVDI DVR

HOSPITAL NAME

Blandford AH

REFERRING VET

Amber Cull-Fournier



The information and recommendations provided are based on the images presented by the referring veterinarian. No evaluation can be communicated regarding pathology that was not visible in the image/video clips provided.

INVOICE

12916

Heike Rudolf, DVM, Dr. med. vet., DipECVDI, DVR

Thank you for this referral. If the clinical or image interpretation does not parallel your findings or if I can be of any further assistance please contact me.

DATE

8/31/21



PATIENT dr.h.rudorf@gmail.com

Belle Spawn Cull
Fournier

SPECIES

Feline

BREED

DLH

SEX

Spayed Female

AGE

13 Years

INTERPRETED BY

Heike Rudorf, DVM,
Dr. med. Vet.,
DipECVDI DVR

HOSPITAL NAME

Blandford AH

REFERRING VET

Amber Cull-Fournier

INVOICE

12916

DATE

8/31/21