



PATIENT

Udo Dudnic

PRESENTING CLINICAL SIGNS

Diarrhea on and off started two weeks ago. vomited 3 times within the two weeks, last vomit was 4 days ago. Still eating Ok. Normal activity level. Heart murmur grade 3-4/6 detected 10 months ago. No coughing.

SPECIES

Abnormal PE/Chem/CBC/UA Results: Blood work in house unremarkable / normal, fecal analysis waiting for results...

Canine

RADIOGRAPHIC STUDY OF THORAX AND ABDOMEN

BREED

R and L lateral dogogram, VD dogogram

Schnauzer

RADIOGRAPHIC FINDINGS

The body condition score is 6/9 with smooth alternating layers of fat and soft tissue opacity.

SEX

The bony structures appear physiological. The surrounding bony structures are within normal limits.

Male

Thorax

AGE

The lungs are in contact with the thoracic boundaries and the tips are pointed. The lobar vessels are visible, but the tertiary branches are blurred.

10 Years

INTERPRETED BY

The cranial mediastinum is of physiological size and opacity. The trachea runs parallel to the thoracic vertebrae and dips at the carina.

Heike Rudolf, DVM,
Dr. med. Vet.,
DipECVDDI DVR

The cardiac silhouette occupies 85% of the chest height and 3.5 intercostal spaces (VHS 11). The caudal heart border is straight and mild tenting of the L atrium is present.

HOSPITAL NAME

Abdomen

St. Catherine's Animal
Hospital

The abdominal detail is good; diaphragm and abdominal wall are intact.

The liver is located just within the costal arch and the caudo-ventral lobe is pointed.

REFERRING VET

The spleen appears physiological.

DR. BEKHIT

The stomach contains a moderate amount of food; on the VD view the food is located in the fundus and the fundic wall measures up to 0.8cm. The small intestinal loops occupy the central abdomen and appear of homogeneous and physiological size. Colon and rectum contain a moderate amount of fecal matter.

INVOICE

47290

The left renal shadow has a physiological size, shape and opacity; the surfaces are smooth. The right kidney is obscured by intestinal loops. The bladder is located in the abdominal cavity and contains a moderate amount of homogeneous fluid opacity.

DATE

8-30-21

The prostate is located cranial to the pubic brim and has pushed the bladder cranially.

The region of the sublumbar lymph nodes appears physiological.



PATIENT

Udo Dudnic

RADIOGRAPHIC DIAGNOSIS

- Gastric wall thickening
- L sided cardiomegaly, mild
- Interstitial pattern, mild

SPECIES

Canine

INTERPRETATION OF THE FINDINGS & FURTHER RECOMMENDATIONS

BREED

Schnauzer

To identify inflammation or tumor, gastro-intestinal wall thickness and layering have to be assessed ultrasonographically or after administration of liquid Barium. This may have to be followed by biopsies. Food trial may help in cases of IBD before full thickness biopsies are obtained.

SEX

Male

Echocardiography with doppler will help identify mitral regurgitation.

The interstitial lung pattern is a non-specific finding and accentuated by the only fair expansion of the lung field on the VD view. Possible differential diagnoses for a true infiltrate include:

AGE

10 Years

- Edema
- Infection (bacterial, fungal e.g. candida, viral, Rickettsia, Spirochetes, parasitic)
- Inflammation (allergic e.g. eosinophilic bronchopneumonia and PIE, smoke inhalation)
- Fibrosis
- Tumor (e.g. lymphoma)

INTERPRETED BY

Heike Rudolf, DVM,
Dr. med. Vet.,
DipECVDDI DVR

Further evaluation by means of tracheobronchoscopy with bronchoalveolar lavage should be considered if respiratory signs develop and pulmonary edema has been ruled out.

HOSPITAL NAME

St. Catherine's Animal
Hospital

REFERRING VET

DR. BEKHIT

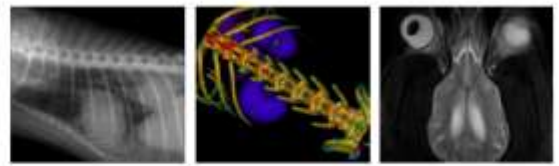
INVOICE

47290

DATE

8-30-21





PATIENT

Udo Dudnic

The information and recommendations provided are based on the images presented by the referring veterinarian. No evaluation can be communicated regarding pathology that was not visible in the image/video clips provided.

SPECIES

Canine

Thank you for this referral. If the clinical or image interpretation does not parallel your findings or if I can be of any further assistance please contact me.

BREED

Schnauzer

Heike Rudolf, DVM, Dr. med. vet., DipECVDI, DVR
Dr.H.Rudorf@gmail.com

SEX

Male

AGE

10 Years

INTERPRETED BY

Heike Rudolf, DVM,
Dr. med. Vet.,
DipECVDI DVR

HOSPITAL NAME

St. Catherine's Animal
Hospital

REFERRING VET

DR. BEKHIT

INVOICE

47290

DATE

8-30-21