



PATIENT PRESENTING CLINICAL SIGNS

Lollie Michaels History: Wakes up during the night gasping for air. Stage B1 valvular disease
Abnormal PE/Chem/CBC/UA Results:

SPECIES RADIOGRAPHIC STUDY OF THE THORAX

Canine The body condition score is 6/9 with smooth alternating layers of fat and soft tissue opacity.
A moderate amount of bridging ventral spondylosis is present.

BREED

GSP The lungs are in contact with the thoracic boundaries and the tips are pointed. The degree of pulmonary expansion is fair at best. The outline of the lobar vessels is blurred, bronchi are highlighted and some show a thickened wall. The cranio-ventral lobes show nodules which are larger than the adjacent tubular vessel and irregular tubule-linear opacities.

SEX

Spayed Female The cranial mediastinum is of physiological size and opacity. The trachea runs parallel to the thoracic vertebrae and dips at the carina.

AGE

12 Years The cardiac silhouette occupies 75% of the chest height and 2.5 intercostal spaces (VHS 10). The caudal heart border is straight and mild tenting of the left atrium appears to be present.

RADIOGRAPHIC DIAGNOSIS

INTERPRETED BY

- Mixed lung pattern
- Nodulo-linear opacities
- Left sided cardiomegaly, mild
- Bridging spondylosis (incidental finding)

Heike Rudolf, DVM,
Dr. med. Vet.,
DipECVDDI DVR

INTERPRETATION OF THE FINDINGS & FURTHER RECOMMENDATIONS

HOSPITAL NAME

New Bridge VP

The changes in the cranial lobes resemble a "tree in bud sign" which is compatible with bronchial plugging and the list of differential diagnoses includes abscess, infection (bacterial, parasitic, fungal), metastases, granulomata, and nodular fibrosis. The mixed lung pattern in the caudal lobes most likely represents a combination of poor lung expansion and infiltrate. A CT examination is needed to verify the finding and show the extent of the infiltrate. Pulmonary edema and infection are the most likely differential diagnoses but tracheoscopy with BAL are needed for a definitive diagnosis. The cardiac changes are compatible with the diagnosis given in the history.

REFERRING VET

Dr. Abina Glennon

TECHNICAL COMMENTS

INVOICE

Rotation of animal

12803

DATE

8/27/21



PATIENT

Lollie Michaels

SPECIES

Canine

BREED

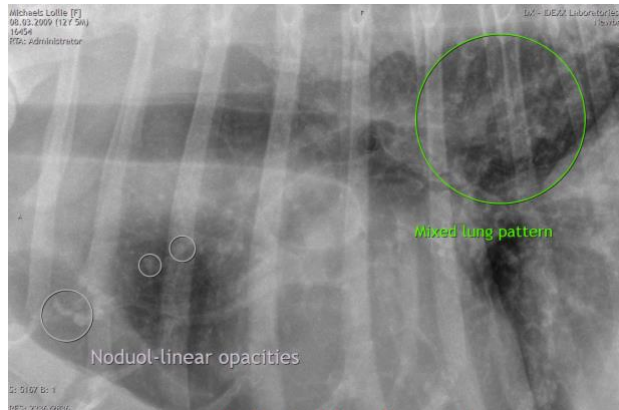
GSP

SEX

Spayed Female

AGE

12 Years



The information and recommendations provided are based on the images presented by the referring veterinarian. No evaluation can be communicated regarding pathology that was not visible in the image/video clips provided.

Thank you for this referral. If the clinical or image interpretation does not parallel your findings or if I can be of any further assistance please contact me.

Heike Rudolf, DVM, Dr. med. vet., DipECVDI, DVR
dr.h.rudorf@gmail.com

INTERPRETED BY

Heike Rudolf, DVM,
Dr. med. Vet.,
DipECVDI DVR

HOSPITAL NAME

New Bridge VP

REFERRING VET

Dr. Abina Glennon

INVOICE

12803

DATE

8/27/21