



**PATIENT PRESENTING CLINICAL SIGNS**

Aspen Padawer History: Pt has been breathing heavy and rDVM stated it was aspiration pneumonia.  
Abnormal PE/Chem/CBC/UA Results:

**SPECIES RADIOGRAPHIC STUDY OF THE THORAX**

Canine The surrounding structures are within normal limits.

The bony structures appear physiological for the age.

**BREED**

French Bulldog The edges of the vessels are blurred and bronchi are highlighted. This is best visible in the right lung on the VD view. A pleural line is present between the right middle and caudal lobes.

**SEX**

The trachea shows a variable height on the two lateral views. Carina as well as main stem bronchi are elevated.

Male

The outlines of the cardiac silhouette is visible and appears globular.

**AGE**

16 Days

**RADIOGRAPHIC DIAGNOSIS**

- Interstitial pattern
- Narrow trachea

**INTERPRETATION OF THE FINDINGS & FURTHER RECOMMENDATIONS**

**INTERPRETED BY**

Heike Rudolf, DVM,  
Dr. med. Vet.,  
DipECVDI DVR

With more than one puppy showing the same clinical signs in one household, the most likely underlying cause for the lung pattern is interstitial pneumonia which is likely to either be due to kennel cough and Bordetella, parainfluenza, herpes, or mycoplasma. Another potential differential diagnosis that should be considered is canine distemper.

**HOSPITAL NAME**

Mountain West VH

Empirical treatment should be initiated. Should the patient remain unresponsive to empirical treatment, further evaluation by means of tracheobronchoscopy with could be considered.

**REFERRING VET**

Allison Bowersox

The animal will have to be assessed for additional anatomical changes associated with BOAS and, should tracheoscopy be carried out to assess the presence of tracheal collapse, bronchial collapse will have to be looked for and a bronchoalveolar lavage obtained.

**INVOICE**

12798

**DATE**

8/27/21



**PATIENT**

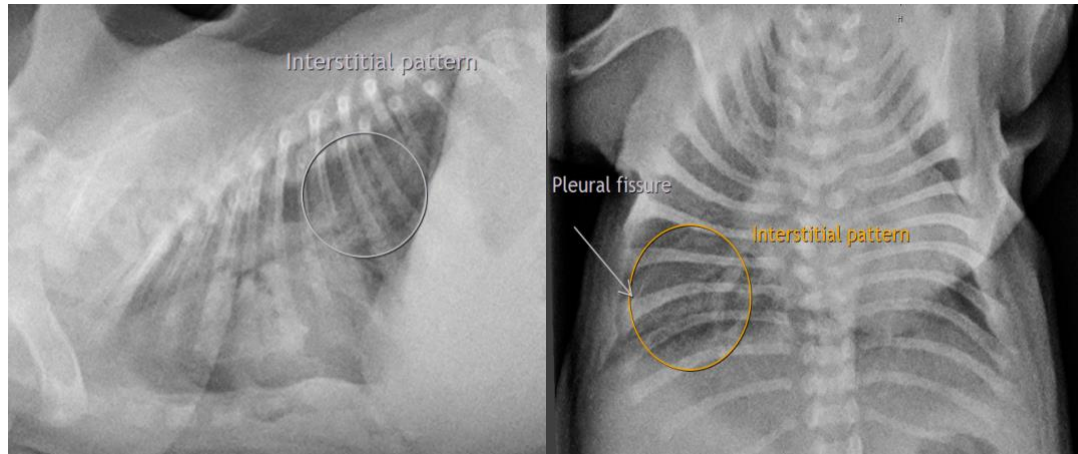
Aspen Padawer

**SPECIES**

Canine

**BREED**

French Bulldog



**SEX**

Male

**The information and recommendations provided are based on the images presented by the referring veterinarian. No evaluation can be communicated regarding pathology that was not visible in the image/video clips provided.**

**AGE**

16 Days

Thank you for this referral. If the clinical or image interpretation does not parallel your findings or if I can be of any further assistance please contact me.

**Heike Rudorf**, DVM, Dr. med. vet., DipECVDI, DVR  
dr.h.rudorf@gmail.com

**INTERPRETED BY**

Heike Rudorf, DVM,  
Dr. med. Vet.,  
DipECVDI DVR

**HOSPITAL NAME**

Mountain West VH

**REFERRING VET**

Allison Bowersox

**INVOICE**

12798

**DATE**

8/27/21