



PATIENT PRESENTING CLINICAL SIGNS

Ash Padawer History: Pt has been breathing heavy and rDVM stated it was aspiration pneumonia. Abnormal PE/Chem/CBC/UA Results:

SPECIES RADIOGRAPHIC STUDY OF THE THORAX

Canine The surrounding structures are within normal limits.

The caudal sternebrae are deviated dorsally, displacing the heart.

BREED

French Bulldog A general, marked decreased vascular outline with bronchial enhancement is present. The degree of pulmonary expansion is fair at best.

SEX

Male The trachea is narrow and at the level of ribs 2 hardly visible.

The cardiac outline is obscured on both lateral views and ill-defined on the DV.

RADIOGRAPHIC DIAGNOSIS

AGE

- Pectus excavatum
- Tracheal narrowing, localized
- Tracheal hypoplasia
- Interstitial pattern

16 Days

INTERPRETED BY INTERPRETATION OF THE FINDINGS & FURTHER RECOMMENDATIONS

Heike Rudolf, DVM, Dr. med. Vet., DipECVDI DVR The combination of pectus excavatum and tracheal narrowing will already result in breathing difficulties, the localized narrowing will need to be confirmed on tracheoscopy though. Additional changes associated with BOAS are likely and will worsen the prognosis.

HOSPITAL NAME

Mountain West VH The interstitial pattern here is rather pronounced, even for a puppy, and infiltrate or a combination of infiltrate and underinflation is likely. In immature patients the most likely underlying cause is interstitial pneumonia which is likely to either be due to kennel cough and Bordetella, parainfluenza, herpes, or mycoplasma. Another potential differential diagnosis that should be considered is canine distemper.

REFERRING VET

Allison Bowersox Empirical treatment should be initiated. Should the patient remain unresponsive to empirical treatment, further evaluation by means of tracheobronchoscopy with bronchoalveolar lavage could be considered.

INVOICE

12797

DATE

8/27/21



PATIENT

Ash Padawer

SPECIES

Canine

BREED

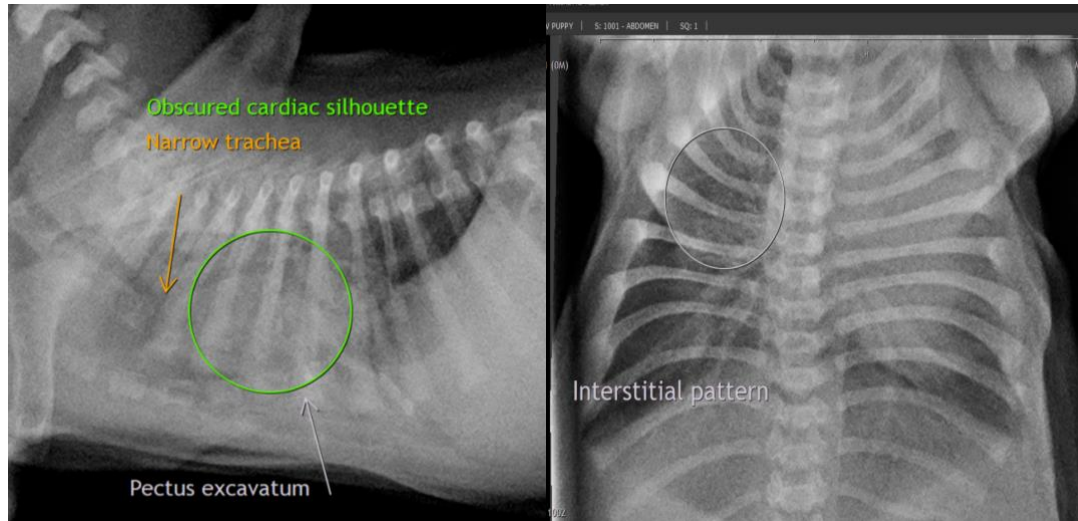
French Bulldog

SEX

Male

AGE

16 Days



The information and recommendations provided are based on the images presented by the referring veterinarian. No evaluation can be communicated regarding pathology that was not visible in the image/video clips provided.

Thank you for this referral. If the clinical or image interpretation does not parallel your findings or if I can be of any further assistance please contact me.

INTERPRETED BY

Heike Rudorf, DVM, Dr. med. vet., DipECVDI, DVR
dr.h.rudorf@gmail.com

Heike Rudorf, DVM,
Dr. med. Vet.,
DipECVDI DVR

HOSPITAL NAME

Mountain West VH

REFERRING VET

Allison Bowersox

INVOICE

12797

DATE

8/27/21