



**PATIENT PRESENTING CLINICAL SIGNS**

**PATIENT** Stevie Nicholls **PRESENTING CLINICAL SIGNS** History: was in kennel for a week, came back with cough, was vaccinated for kennel cough in July, sending x-rays to evaluate chest and trachea

**SPECIES** Abnormal PE/Chem/CBC/UA Results: no bw

**Canine RADIOGRAPHIC STUDY OF THE THORAX**

The body condition score is 5/9.

**BREED**

Chinese Crested

The bony structures appear physiological.

**SEX**

Neutered Male

The lungs are in contact with the thoracic boundaries and the tips are pointed. The lobar vessels are clearly visible to the tertiary branches. The left caudal bronchial tree shows slightly thickened bronchial walls on the VD view.

**AGE**

19 Months

The cranial mediastinum is of physiological size and opacity. The trachea diverges from the thoracic vertebrae.

The cardiac silhouette occupies 75% of the chest height and 2.5 intercostal spaces. No chamber or outflow tract enlargement is evident.

**RADIOGRAPHIC DIAGNOSIS**

- Peribronchial infiltrate, localized and mild

**INTERPRETED BY**

Heike Rudolf, DVM,  
Dr. med. Vet.,  
DipECVDI DVR

**INTERPRETATION OF THE FINDINGS & FURTHER RECOMMENDATIONS**

The lung pattern suggests bronchitis. Primary inflammatory, non-infectious causes (e.g. neutrophilic, eosinophilic, allergic), as well as infectious causes (bacterial, viral, parasitic) need to be considered.

**HOSPITAL NAME**

St. Catharine's AH

The most likely underlying cause is interstitial pneumonia which, in immature patients, is likely to either be due to kennel cough and Bordetella, parainfluenza, herpes, or mycoplasma. Should the patient remain unresponsive to empirical treatment, further evaluation by means of trachea-bronchoscopy with bronchoalveolar lavage could be considered.

**REFERRING VET**

Dr. Masoud

Palliative daily inhalation with a sodium-chloride inhalant may be beneficial.

**TECHNICAL COMMENTS**

**INVOICE**

12777

Both lateral views are rotated.

**DATE**

8/26/21



**PATIENT**

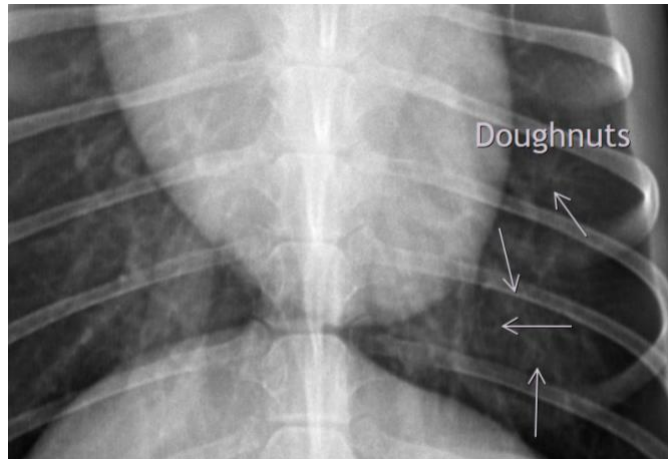
Stevie Nicholls

**SPECIES**

Canine

**BREED**

Chinese Crested



**SEX**

Neutered Male

**The information and recommendations provided are based on the images presented by the referring veterinarian. No evaluation can be communicated regarding pathology that was not visible in the image/video clips provided.**

**AGE**

19 Months

Thank you for this referral. If the clinical or image interpretation does not parallel your findings or if I can be of any further assistance please contact me.

**Heike Rudorf**, DVM, Dr. med. vet., DipECVDI, DVR  
dr.h.rudorf@gmail.com

**INTERPRETED BY**

Heike Rudorf, DVM,  
Dr. med. Vet.,  
DipECVDI DVR

**HOSPITAL NAME**

St. Catharine's AH

**REFERRING VET**

Dr. Masoud

**INVOICE**

12777

**DATE**

8/26/21