



PATIENT PRESENTING CLINICAL SIGNS

Dudley Bell History: Same history as last year
Abnormal PE/Chem/CBC/UA Results:

SPECIES RADIOGRAPHIC STUDY OF THE THORAX

Canine The lungs are in contact with the thoracic boundaries and the tips are pointed. The lobar vessels are clearly visible to the tertiary branches. On the VD view, the vascular outline of caudal vena cava and pulmonary vessels at the same level is slightly blurred.

BREED

Miniature Poodle The tracheal lumen is reduced in the cervical region by a dorsal soft tissue line.
The other structures appear physiological.

SEX RADIOGRAPHIC DIAGNOSIS

Neutered Male

- Tracheal collapse
- Localized interstitial pattern

AGE INTERPRETATION OF THE FINDINGS & FURTHER RECOMMENDATIONS

13 Years Tracheal collapse alone can be due to a weakened dorsal tracheal ligament. Tracheal as well as tracheo-bronchial collapse is usually caused by chondromalacia and is thus due to an altered cartilage development which may go unnoticed until physical circumstances (such as stress, running, excitement) or disease (e.g. pneumonia, bronchitis, L cardiac enlargement) reduces the ease of airflow.

INTERPRETED BY

Heike Rudolf, DVM, Dr. med. Vet., DipECVDI DVR The localized interstitial lung pattern is a non-specific finding and most likely due to a previous right lateral recumbency. Possible differential diagnoses for a true infiltrate include:

HOSPITAL NAME

Gentle Doctor AH

- Infection (bacterial, fungal e.g. candida, viral, Rickettsia, Spirochetes, parasitic)
- Inflammation (allergic e.g. eosinophilic bronchopneumonia and PIE, smoke inhalation)
- Fibrosis

Echocardiography to assess mitral valve and left atrial size and bronchoscopy to obtain a BAL is recommended. Should an underlying disease be present treatment may improve the clinical signs.

REFERRING VET

Dr. P. Bashara

INVOICE

12766

DATE

8/26/21



PATIENT

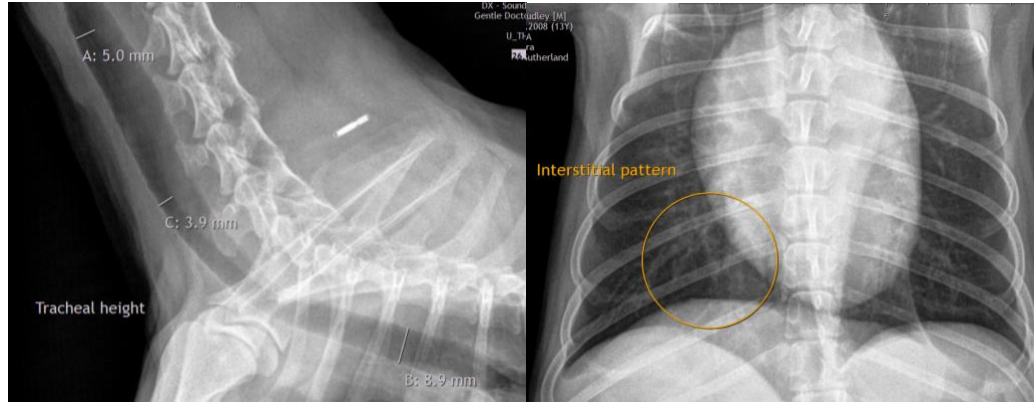
Dudley Bell

SPECIES

Canine

BREED

Miniature Poodle



SEX

Neutered Male

AGE

13 Years

The information and recommendations provided are based on the images presented by the referring veterinarian. No evaluation can be communicated regarding pathology that was not visible in the image/video clips provided.

Thank you for this referral. If the clinical or image interpretation does not parallel your findings or if I can be of any further assistance please contact me.

Heike Rudolf, DVM, Dr. med. vet., DipECVDI, DVR
dr.h.rudorf@gmail.com

INTERPRETED BY

Heike Rudolf, DVM,
Dr. med. Vet.,
DipECVDI DVR

HOSPITAL NAME

Gentle Doctor AH

REFERRING VET

Dr. P. Bashara

INVOICE

12766

DATE

8/26/21