



**PATIENT PRESENTING CLINICAL SIGNS**

Dexter Varela History: P ate sock 2 days ago.  
Abnormal PE/Chem/CBC/UA Results:

**SPECIES RADIOGRAPHIC STUDY OF THE ABDOMEN**

Canine The body condition score is 7/9 with smooth alternating layers of fat and soft tissue opacity.

The surrounding bony structures are within normal limits.

**BREED**

Pitbull The stomach contains a moderate amount of food; the small intestinal loops occupy the centro-ventral abdomen and appear of homogeneous and physiological size. Colon and rectum contain a moderate amount of fecal matter which appears striated in some areas.

**SEX**

The other abdominal structures appear physiological.

Male

**RADIOGRAPHIC DIAGNOSIS**

- Foreign body colon

**AGE**

1 Year 3 Months

**INTERPRETATION OF THE FINDINGS & FURTHER RECOMMENDATIONS**

The straited appearance in the colon suggests that the cloth foreign object has already left the small intestine and the feces should be checked to see if the sock has been passed in its entirety; if not, or vomiting or abdominal discomfort be/remain to be present, abdominal ultrasonography should be employed to check if parts of the cloth foreign body have resulted in a linear foreign body.

**INTERPRETED BY**

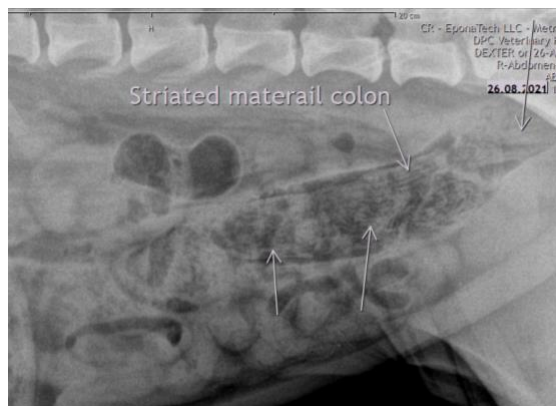
Heike Rudorf, DVM,  
Dr. med. Vet.,  
DipECVDI DVR

**HOSPITAL NAME**

DPC Veterinary H

**REFERRING VET**

Dr. White



**INVOICE**

12775

The information and recommendations provided are based on the images presented by the referring veterinarian. No evaluation can be communicated regarding pathology that was not visible in the image/video clips provided.

**DATE**

8/26/21

Thank you for this referral. If the clinical or image interpretation does not parallel your findings or if



**PATIENT** I can be of any further assistance please contact me.

Dexter Varela **Heike Rudolf**, DVM, Dr. med. vet., DipECVDI, DVR  
dr.h.rudorf@gmail.com

**SPECIES**

Canine

**BREED**

Pitbull

**SEX**

Male

**AGE**

1 Year 3 Months

**INTERPRETED BY**

Heike Rudolf, DVM,  
Dr. med. Vet.,  
DipECVDI DVR

**HOSPITAL NAME**

DPC Veterinary H

**REFERRING VET**

Dr. White

**INVOICE**

12775

**DATE**

8/26/21