



PATIENT PRESENTING CLINICAL SIGNS

Lola Leech History: Lump at the dorsal aspect of the LFL , still the same , after a round of Abs & steroid . Sending a Chest x-ray to see if it metastasized to lung.

SPECIES Abnormal PE/Chem/CBC/UA Results: CBC: Hemogram: WNL, Leukogram: stress, Thrombogram:WNL
Chemistries: Kidney:WNL, Liver: MODERATE ELEVATION OF ALP R/O stress , steroid tx., liver disease vs cushing disease , rest:WNL Lytes: WNL
Canine

RADIOGRAPHIC STUDY OF THE THORAX

BREED

Chihuahua Mix The body condition score is 8/9 with a large fatty lump on the dorsum of sacrum and tail.

The bones are well mineralized with good trabecular structure and smooth surfaces. The disc spaces appear homogeneous in width.

SEX

Spayed Female The bony structures appear physiological. The surrounding bony structures are within normal limits.

The degree of pulmonary expansion is fair. The lungs are in contact with the thoracic boundaries and the tips are pointed. The lobar vessels are clearly visible.

AGE

6 Years The cranial mediastinum is superimposed by the fore legs but appears to have a physiological size. The trachea runs parallel to the thoracic vertebrae and dips slightly at the carina.

INTERPRETED BY

The cardiac silhouette occupies 80% of the chest height and 3.5 intercostal spaces. The caudal heart border is straight and the left caudal main stem bronchus is slightly displaced laterally.

Heike Rudolf, DVM,
Dr. med. Vet.,
DipECVDI DVR

RADIOGRAPHIC DIAGNOSIS

- I can see no metastases
- Possible left sided cardiomegaly

HOSPITAL NAME

INTERPRETATION OF THE FINDINGS & FURTHER RECOMMENDATIONS

St. Catharine's AH

Small metastases will only be visible on CT.

REFERRING VET

The cardiac changes are mild and it is possible that pericardial fat is causing the distortion thus echocardiography is recommended to check left atrial size and the mitral valve.

Dr. Masoud

TECHNICAL COMMENTS

INVOICE

Ungloved human fingers in primary beam on VD view.

12633

DATE

8/20/21



PATIENT

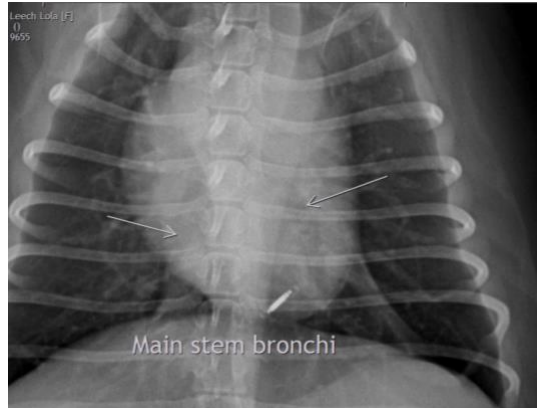
Lola Leech

SPECIES

Canine

BREED

Chihuahua Mix



The information and recommendations provided are based on the images presented by the referring veterinarian. No evaluation can be communicated regarding pathology that was not visible in the image/video clips provided.

SEX

Spayed Female

Thank you for this referral. If the clinical or image interpretation does not parallel your findings or if I can be of any further assistance please contact me.

AGE

6 Years

Heike Rudolf, DVM, Dr. med. vet., DipECVDI, DVR
dr.h.rudorf@gmail.com

INTERPRETED BY

Heike Rudolf, DVM,
Dr. med. Vet.,
DipECVDI DVR

HOSPITAL NAME

St. Catharine's AH

REFERRING VET

Dr. Masoud

INVOICE

12633

DATE

8/20/21