



**PATIENT PRESENTING CLINICAL SIGNS**

**Hercules Vera** History: 12y old, when he gets excited he faints. Coughing a lot during night. Vomiting on and off. The retro pharynx lymph nodes are enlarged as well as the pre scapular lymph nodes.

**SPECIES** Abnormal PE/Chem/CBC/UA Results:

**Canine RADIOGRAPHIC STUDY OF THE THORAX**

The body condition score is 7/9 with smooth alternating layers of fat and soft tissue opacity.

**BREED** The bony structures appear physiological.

**Boxer**

**SEX**

**Neutered Male**

The degree of pulmonary expansion is poor. The caudal lung lobes are in contact with the thoracic boundaries and the tips are pointed; the vascular outline is obscured and the bronchi are highlighted. The cranial lobes appear rounded on the lateral view and are located level with ribs 3. A semicircular soft tissue opacity appears to be superimposed onto the cranio-ventral lung lobes and the terminal 1/2 of the thoracic trachea is elevated in a semicircular fashion. The carina is located at the same level as the rest of the trachea. On the DV views the tracheal path seems to coincide with that of the sternum, which is located to the left of the vertebral column.

**AGE**

**12 Years**

The caudal heart border is obscured by the overlying dome of the diaphragm. The carina is located just ventral to the thoracic spine suggesting a height of the cardiac silhouette of 80% of the chest height.

**INTERPRETED BY RADIOGRAPHIC DIAGNOSIS**

**Heike Rudolf, DVM,  
Dr. med. Vet.,  
DipECVDI DVR**

- Possible cranial mediastinal mass
- Possible heart base mass
- Interstitial pattern

**HOSPITAL NAME INTERPRETATION OF THE FINDINGS & FURTHER RECOMMENDATIONS**

**Wilson Road VC**

The changes are highly suggestive of mediastinal pathologies (e.g. lymphoma, especially considering the already existing lymphadenomegalies) and further imaging is recommended. The best imaging modality would be a CT. However, should this not be available, manually inflated, straight lateral and DV views with a grid can be obtained. Alternatively, thoracic ultrasound can be used; this would facilitate obtaining biopsies and also allow cardiac assessment. Another option is to obtain samples from the palpably enlarged lymph nodes and await pathology results.

**REFERRING VET**

**Dr. Ehab Yessa**

**INVOICE** The generalized interstitial lung pattern is a non-specific finding and accentuated by the poor expansion of the lung field. Possible differential diagnoses for a true infiltrate include:

**12614**

- Tumor (e.g. lymphoma)
- Fibrosis
- Infection (bacterial, fungal e.g. candida, viral, Rickettsia, Spirochetes, parasitic)

**DATE**

**8/19/21**



**PATIENT**

- Inflammation (allergic e.g. eosinophilic bronchopneumonia and PIE, smoke inhalation)

Hercules Vera

Further evaluation by means of tracheobronchoscopy with bronchoalveolar lavage can be considered after the biopsies.

**SPECIES**

Canine

**TECHNICAL COMMENTS**

Only jpg images were submitted. The transformation from DICOM to jpg reduces the image quality and only allows limited manipulation of the image. More subtle lesions can thus easily be missed. For the best possible imaging reports I suggest submitting DICOM images in the future. The lateral views are rotated.

**BREED**

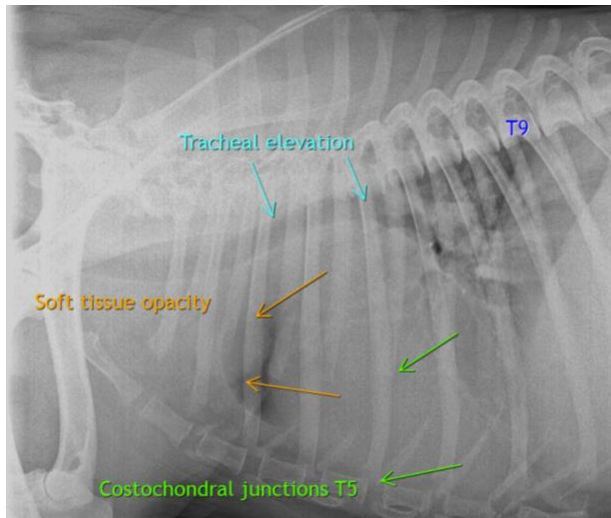
Boxer

**SEX**

Neutered Male

**AGE**

12 Years



**INTERPRETED BY**

Heike Rudolf, DVM,  
Dr. med. Vet.,  
DipECVDDI DVR

**The information and recommendations provided are based on the images presented by the referring veterinarian. No evaluation can be communicated regarding pathology that was not visible in the image/video clips provided.**

**HOSPITAL NAME**

Wilson Road VC

Thank you for this referral. If the clinical or image interpretation does not parallel your findings or if I can be of any further assistance please contact me.

**REFERRING VET**

Dr. Ehab Yessa

**Heike Rudolf**, DVM, Dr. med. vet., DipECVDDI, DVR  
dr.h.rudorf@gmail.com

**INVOICE**

12614

**DATE**

8/19/21



**PATIENT**

Hercules Vera

**SPECIES**

Canine

**BREED**

Boxer

**SEX**

Neutered Male

**AGE**

12 Years

**INTERPRETED BY**

Heike Rudorf, DVM,  
Dr. med. Vet.,  
DipECVDI DVR

**HOSPITAL NAME**

Wilson Road VC

**REFERRING VET**

Dr. Ehab Yessa

**INVOICE**

12614

**DATE**

8/19/21