



PATIENT PRESENTING CLINICAL SIGNS

PATIENT Bear Alexander
PRESENTING CLINICAL SIGNS History: History of laryngeal paralysis past year. Intermittent coughing past 6 months, getting worse. Pt will get excited or active and struggle to breath becoming cyanotic. Survey chest rads included for review.

SPECIES Abnormal PE/Chem/CBC/UA Results:

Canine

RADIOGRAPHIC STUDY OF THE THORAX

BREED The body condition score is 6/9 with smooth alternating layers of fat and soft tissue opacity.

Poodle Mix A moderate amount of ventral spondylosis is present along the mid-thoracic and cranial lumbar vertebrae.

SEX The DV view is deeply and the lateral view moderately inspiratory. The lungs are in contact with the thoracic boundaries and the tips are pointed. The lobar vessels are clearly visible to the tertiary branches.

Neutered Male

AGE The cranial mediastinum is of physiological size and opacity. The trachea diverges from the thoracic vertebrae and the carina is located at T5.

12 Years 9 Months

The cardiac silhouette occupies 75% of the chest height and 2.5 intercostal spaces. No chamber or outflow tract enlargement is evident.

INTERPRETED BY RADIOGRAPHIC DIAGNOSIS

Heike Rudolf, DVM,
Dr. med. Vet.,
DipECVDI DVR

- I can see no mediastinal mass or pulmonary infiltrate
- Spondylosis (incidental finding)

HOSPITAL NAME INTERPRETATION OF THE FINDINGS & FURTHER RECOMMENDATIONS

Reid VH

The thoracic radiographs appear physiological and surgery for laryngeal paralysis can be performed.

REFERRING VET

Dr. Diane Heider

INVOICE

12615

DATE

8/19/21



PATIENT

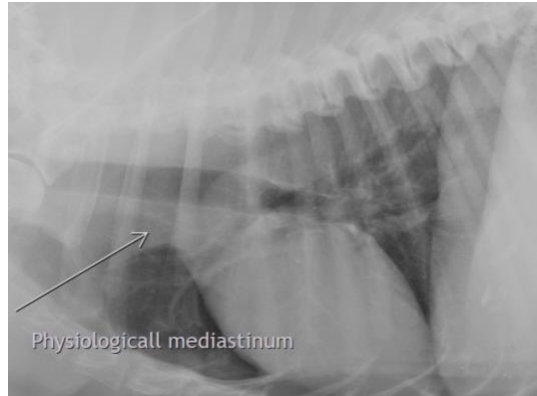
Bear Alexander

SPECIES

Canine

BREED

Poodle Mix



SEX

Neutered Male

The information and recommendations provided are based on the images presented by the referring veterinarian. No evaluation can be communicated regarding pathology that was not visible in the image/video clips provided.

AGE

12 Years 9 Months

Thank you for this referral. If the clinical or image interpretation does not parallel your findings or if I can be of any further assistance please contact me.

Heike Rudolf, DVM, Dr. med. vet., DipECVDI, DVR
dr.h.rudorf@gmail.com

INTERPRETED BY

Heike Rudolf, DVM,
Dr. med. Vet.,
DipECVDI DVR

HOSPITAL NAME

Reid VH

REFERRING VET

Dr. Diane Heider

INVOICE

12615

DATE

8/19/21