



PATIENT PRESENTING CLINICAL SIGNS

Checkers Crowell History: Presented for evaluation of general weakness. Abnormal PE/Chem/CBC/UA Results: HR 130, BCS 8/9, RR panting, generalized weakness, significantly worse in pelvic limbs, decrease cp in pelvic limbs, reflexes intact, able to ambulate on forelimbs but weak, muscle atrophy over all 4 limbs

SPECIES

Canine

RADIOGRAPHIC STUDY OF THE T - AND L - SPINE

A large amount of subcutaneous fat is present, especially dorsal to the spine. On the VD thoracic view a lipoma is located on the right cranial thoracic wall.

BREED

Border Collie

Number and shape of the vertebrae are physiological. The skeletal structures are well mineralized and have smooth surfaces. The facet joints appear to be congruent. The disc spaces appear to be of homogeneous width.

SEX

Spayed Female

A pendulous ventral abdominal wall is present. The ventral liver lobe is located just within the costal arch.

RADIOGRAPHIC DIAGNOSIS

AGE

10 Years

- Pendulous ventral abdominal wall
- Obesity

INTERPRETATION OF THE FINDINGS & FURTHER RECOMMENDATIONS

INTERPRETED BY

Heike Rudorf, DVM,
Dr. med. Vet.,
DipECVDDI DVR

Accurate positioning of the spine is difficult even under G.A. and cord compression can only be identified with myelography or in cross sectional imaging. Depending on the severity of the neurological signs, CT or MRI will be necessary in case an extruded disc needs to be removed.

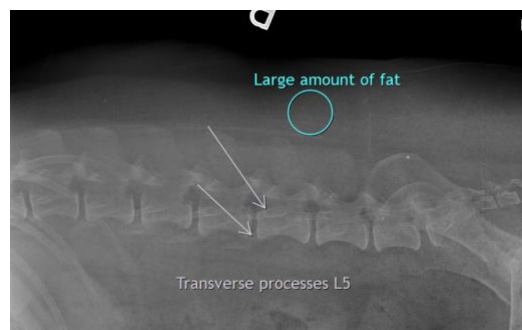
HOSPITAL NAME

Torch Lake VC

Obesity and pendulous ventral abdominal wall in association with loss of muscle mass and weakness can be first signs of Cushing's disease and should the liver enzymes be elevated, and ACTH stimulation test is recommended. Hypothyroidism should be ruled out. Eosinophilic myositis is also a differential diagnosis for muscle weakness. In the absence of a megaesophagus acquired myasthenia gravis seems unlikely, but if all other diseases have been ruled out, should be checked for.

REFERRING VET

Adrienne Waffle



INVOICE

16853

DATE

8/12/22



PATIENT The information and recommendations provided are based on the images presented by the referring veterinarian/sonographer. No evaluation can be communicated regarding pathology that was not visible in the image/video clips provided.

Checkers Crowell

Thank you for this referral. If the clinical or image interpretation does not parallel your findings or if I can be of any further assistance please contact me.

SPECIES

Canine **Heike Rudolf**, DVM, Dr. med. vet., DipECVDI, DVR
dr.h.rudorf@gmail.com

BREED

Border Collie

SEX

Spayed Female

AGE

10 Years

INTERPRETED BY

Heike Rudolf, DVM,
Dr. med. Vet.,
DipECVDI DVR

HOSPITAL NAME

Torch Lake VC

REFERRING VET

Adrienne Waffle

INVOICE

16853

DATE

8/12/22