



**PATIENT PRESENTING CLINICAL SIGNS**

Riley Lanzer History: left radius and ulna fracture repair. had surgery on 6/30/23. LT carpal swelling

**RADIOGRAPHIC STUDY OF THE ELBOWS**

**SPECIES**

Canine

A soft tissue swelling surrounds the leg in the region of the plate. The dorsal outline is irregular for approx. 4cm suggesting an ulcerated or damaged surface.

**BREED**

Poodle Mix

A plate is located dorsal to the distal radius. Screws have been placed through the proximal five holes and their tips have entered the ulna. Two screws are angled towards one another in the distal two holes and also enter the ulna. The implants are intact, and no lysis surrounds them. The former fracture site appears to have healed with increased opacity in the distal medullary cavity. A small amount of new bone is present on the palmar radial fracture site. A thin, radiolucent line is visible in the radius on the proximal aspect increased opacity in the radial medulla, level with the bony gap in the ulna. An approx. 0.5cm long gap is present in the distal ulna at the level of the plate without screws. The bony edges are rounded.

**SEX**

Spayed Female

**RADIOGRAPHIC DIAGNOSIS**

**AGE**

3 Years

Radius

- Soft tissue swelling associated with implants
- Damaged cranial surface of swelling

Ulna

- Non-union

**INTERPRETED BY**

Heike Rudorf, DVM,  
Dr. med. Vet.,  
DipECVDI DVR

**INTERPRETATION OF THE FINDINGS & FURTHER RECOMMENDATIONS**

The swelling surrounds the implant site and is irregular cranially, suggesting damage or ulceration which may have been caused by licking due to irritation. I can see no changes associated with the implants and the bone seems to have healed in the proximo-distal plain. A low grade, recent infection associated with the soft tissue swelling cannot be ruled out. Obtaining a cranio-caudal view is necessary to ensure healing in the latero-medial direction before removal of the implants. Hematology will provide information regarding leukocytosis.

**HOSPITAL NAME**

Animal Surgical  
Center-East Meadow

**REFERRING VET**

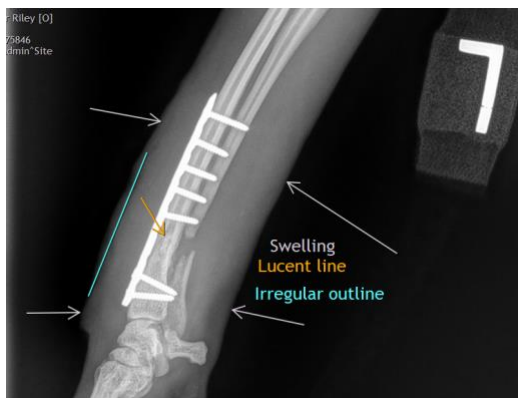
Juniper Valley AH

**INVOICE**

23893

**DATE**

8/10/23





**PATIENT**

Riley Lanzer

**The information and recommendations provided are based on the images presented by the referring veterinarian/sonographer. No evaluation can be communicated regarding pathology that was not visible in the image/video clips provided.**

**SPECIES**

Canine

Thank you for this referral. If the clinical or image interpretation does not parallel your findings or if I can be of any further assistance please contact me.

**Heike Rudolf**, DVM, Dr. med. vet., DipECVDI, DVR  
info@sonopath.com

**BREED**

Poodle Mix

**SEX**

Spayed Female

**AGE**

3 Years

**INTERPRETED BY**

Heike Rudolf, DVM,  
Dr. med. Vet.,  
DipECVDI DVR

**HOSPITAL NAME**

Animal Surgical  
Center-East Meadow

**REFERRING VET**

Juniper Valley AH

**INVOICE**

23893

**DATE**

8/10/23