



PATIENT PRESENTING CLINICAL SIGNS

Buddy Corbett History: DDX: Heart disease, pancreatitis, liver disease, kidney disease
 Abnormal PE/Chem/CBC/UA Results: Blood work and urine show urinary tract infection and elevated ALT, P is getting Apoquel on chronic basis, that may be why liver enzymes high.

SPECIES RADIOGRAPHIC STUDY OF THE THORAX

Canine The body condition score is 5/9 with smooth alternating layers of fat and soft tissue opacity.

The bony structures appear physiological.

BREED

Chihuahua The degree of pulmonary expansion is good. The lungs are in contact with the thoracic boundaries and the tips are pointed. The lobar vessels are clearly visible to the tertiary branches and have a physiological width. The bronchial tree is thin walled and tapers uniformly towards the periphery.

SEX

Male The cranial mediastinum is of physiological size and opacity. The trachea runs parallel to the thoracic vertebrae and dips at the carina. In the caudal cervical region, a soft tissue opacity reduces the air-filled lumen from dorsally to approx. ¼ of the size of the thoracic trachea.

AGE

13 Years The cardiac silhouette occupies 85% of the chest height and 3 intercostal spaces (VHS 10.5). The caudal border appears slightly straight but no obvious chamber or outflow tract enlargement is evident.

RADIOGRAPHIC DIAGNOSIS

- Tracheal collapse
- Possible, mild left sided enlargement

INTERPRETED BY

Heike Rudolf, DVM,
 Dr. med. Vet.,
 DipECVDI DVR

INTERPRETATION OF THE FINDINGS & FURTHER RECOMMENDATIONS

Tracheal collapse alone can be due to a weakened dorsal tracheal ligament. Tracheal in combination with bronchial collapse is usually due to an altered cartilage development which may go unnoticed until physical circumstances (such as stress, running, excitement) or disease (e.g. pneumonia, bronchitis, L cardiac enlargement) reduces the ease of airflow. Echocardiography to assess mitral valve and left atrial size as well as bronchoscopy to obtain a BAL is recommended. Should an underlying disease be present treatment may improve the clinical signs.

HOSPITAL NAME

St. Catherine's AH

TECHNICAL COMMENTS

REFERRING VET

Surname on images: Bowie

Dr. William

INVOICE

23917

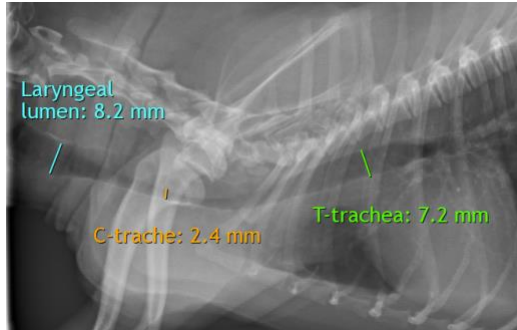
DATE

8/10/23



PATIENT

Buddy Corbett



SPECIES

Canine

BREED

Chihuahua

The information and recommendations provided are based on the images presented by the referring veterinarian/sonographer. No evaluation can be communicated regarding pathology that was not visible in the image/video clips provided.

SEX

Thank you for this referral. If the clinical or image interpretation does not parallel your findings or if I can be of any further assistance please contact me.

Male

Heike Rudolf, DVM, Dr. med. vet., DipECVDI, DVR
info@sonopath.com

AGE

13 Years

INTERPRETED BY

Heike Rudolf, DVM,
Dr. med. Vet.,
DipECVDI DVR

HOSPITAL NAME

St. Catherine's AH

REFERRING VET

Dr. William

INVOICE

23917

DATE

8/10/23