



PATIENT PRESENTING CLINICAL SIGNS

Sawyer Zimmerman

History: HISTORY: Oral ulcerations, sores on the trunk about 3 weeks ago they seem to respond to steroids. There was a recurrence of lesions. Biopsy and culture revealed 3 different bacteria, 1 resistant. In addition it revealed what appeared to be a cytotoxic reaction to medication, even though we were on no medications when it started, and an autoimmune disease. The dog is currently on chloramphenicol and immunosuppressive doses of Prednisone and cyclosporine. There has been great response in the oral cavity, but the skin seems slow to follow. X-rays and ultrasound done to look for possible underlying cancer that could be causing a paraneoplastic dermatitis.

SPECIES

Canine

BREED

Border Collie

Abnormal PE/Chem/CBC/UA Results: EXAM: NO ULCERS OR EROSIONS OR DISCOLORATION NOTED. STAGE I DENTAL DISEASE. OOZING, PAINFUL, SCABBING SORES ON FACE, PROXIMAL LIMBS, TRUNK. NO RECENT LABS

RADIOGRAPHIC STUDY OF THE THORAX

SEX

Neutered Male

The body condition score is 5/9 with irregular opacities in the ventral thoracic soft tissues.

The bony structures appear physiological.

AGE

7 Years 4 Months

The lungs are in contact with the thoracic boundaries and the tips are pointed. The lobar vessels are clearly visible to the tertiary branches. The bronchial tree is thin walled and tapers uniformly towards the periphery.

The cranial mediastinum is of physiological size and opacity. The trachea diverges from the thoracic vertebrae and the carina is located at T5. A small amount of air is present in the esophagus.

INTERPRETED BY

Heike Rudolf, DVM,
Dr. med. Vet.,
DipECVDI DVR

The cardiac silhouette occupies 75% of the chest height and 2.5 intercostal spaces. No chamber or outflow tract enlargement is evident.

RADIOGRAPHIC DIAGNOSIS

- Irregular ventral soft tissue opacities

HOSPITAL NAME

Elizabeth AH

INTERPRETATION OF THE FINDINGS & FURTHER RECOMMENDATIONS

I can see no evidence of mass lesions. The irregular opacities most likely represent the skin lesions.

REFERRING VET

Leon Anderson, DVM

INVOICE

16589

DATE

7/29/22



PATIENT

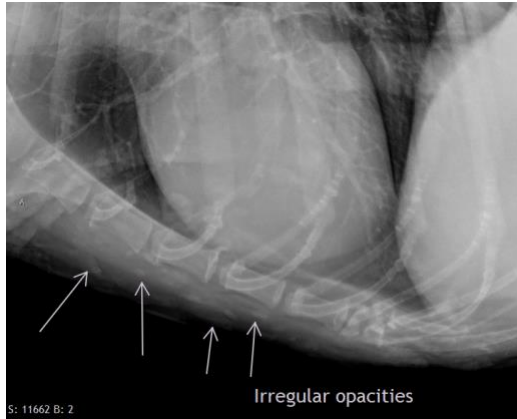
Sawyer Zimmerman

SPECIES

Canine

BREED

Border Collie



SEX

Neutered Male

AGE

7 Years 4 Months

The information and recommendations provided are based on the images presented by the referring veterinarian/sonographer. No evaluation can be communicated regarding pathology that was not visible in the image/video clips provided.

Thank you for this referral. If the clinical or image interpretation does not parallel your findings or if I can be of any further assistance please contact me.

Heike Rudolf, DVM, Dr. med. vet., DipECVDI, DVR
dr.h.rudorf@gmail.com

INTERPRETED BY

Heike Rudolf, DVM,
Dr. med. Vet.,
DipECVDI DVR

HOSPITAL NAME

Elizabeth AH

REFERRING VET

Leon Anderson, DVM

INVOICE

16589

DATE

7/29/22