



PATIENT PRESENTING CLINICAL SIGNS

Rubble Askett History: Regurgitate / trying to vomit and vomiting sometime after eating. started long time ago Swelling on the left side of the neck comes and back specially after eating. Vomited a lot undigested food while collecting blood sample No heart murmur detected . Concern congenital problem.

SPECIES Abnormal PE/Chem/CBC/UA Results: Blood work in house mild decrease in TP, otherwise unremarkable / normal.
Canine

RADIOGRAPHIC STUDY OF THE THORAX AND ABDOMEN

BREED The body condition score is 4/9.

American Bulldog Skeletal immaturity compatible with the given age is noted.

Thorax

SEX The cervical esophagus is enlarged and displaces the trachea ventrally. It contains mineralized material. An esophageal pouch is located cranial to the heart and contains solid material/gravel sign and air. The same structure is visible to the left of the midline on the VD. The pouch terminates level with rib 4. The trachea is ventrally displaced and approaches the physiologically positioned carina at an acute angle. On the VD the trachea is deviated to the right.
Male

AGE The lungs are in contact with the thoracic boundaries and the tips are pointed. The lobar vessels are clearly visible to the tertiary branches. The bronchial tree is thin walled and tapers uniformly towards the periphery.
12 Weeks

INTERPRETED BY The cardiac silhouette occupies 75% of the chest height, the cranial cardiac outline is superimposed by the pathology and the thymus.
Heike Rudorf, DVM,
Dr. med. Vet.,
DipECVDI DVR

Abdomen

HOSPITAL NAME The poor abdominal detail is in line with the age and low-fat content; diaphragm and abdominal wall are intact.

St. Catharine's AH Mineral material is present dorsal to the cranio-ventral abdominal wall, level with L2.

REFERRING VET RADIOGRAPHIC DIAGNOSIS

Dr. Bekhit • Vascular ring anomaly

INTERPRETATION OF THE FINDINGS & FURTHER RECOMMENDATIONS

INVOICE The disease is congenital and surgical intervention is the only option to improve the clinical signs. The caudal esophagus is not dilated which suggests physiological motility, thus full recovery is possible, especially as esophageal size will reduce relative to the increase in body size. Aspiration pneumonia does not seem to be present at the moment but can develop quickly. The gravel should be removed from the cervical esophagus.
16588

DATE

7/29/22



PATIENT

Rubble Askett

SPECIES

Canine

BREED

American Bulldog

SEX

Male

AGE

12 Weeks

INTERPRETED BY

Heike Rudorf, DVM,
Dr. med. Vet.,
DipECVDI DVR

HOSPITAL NAME

St. Catharine's AH

REFERRING VET

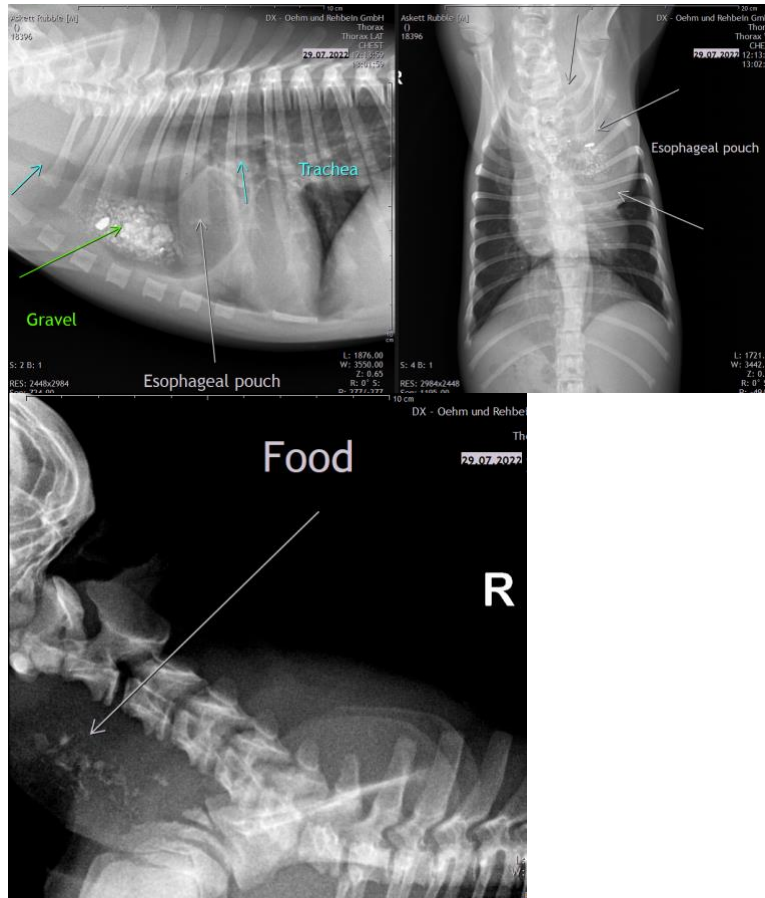
Dr. Bekhit

INVOICE

16588

DATE

7/29/22



The information and recommendations provided are based on the images presented by the referring veterinarian/sonographer. No evaluation can be communicated regarding pathology that was not visible in the image/video clips provided.

Thank you for this referral. If the clinical or image interpretation does not parallel your findings or if I can be of any further assistance please contact me.

Heike Rudorf, DVM, Dr. med. vet., DipECVDI, DVR
dr.h.rudorf@gmail.com



PATIENT

Rubble Askett

SPECIES

Canine

BREED

American Bulldog

SEX

Male

AGE

12 Weeks

INTERPRETED BY

Heike Rudolf, DVM,
Dr. med. Vet.,
DipECVDI DVR

HOSPITAL NAME

St. Catharine's AH

REFERRING VET

Dr. Bekhit

INVOICE

16588

DATE

7/29/22