



**PATIENT**

Remington Johnson

**PRESENTING CLINICAL SIGNS**

History: Dog had fever and swelling just rostral to larynx with probable edema sampled on FNA on July 18, completed course of Amoxiclav 625mg BID x 7 days on July 26. Mass has decreased in size and no longer febrile. Dog is still uncomfortable and is drooling, appetite is decreased, drinking normally, no vomiting, no coughing.

**SPECIES**

Canine

**RADIOGRAPHIC STUDY OF THE NECK**

The soft tissue dorsal to the thyroid cartilage is slightly prominent but the fascial plains are still visible.

**BREED**

Labrador Retriever

I can see no obvious masses or bony abnormalities.

**RADIOGRAPHIC DIAGNOSIS**

**SEX**

- Possible mild retropharyngeal swelling

Neutered Male

**INTERPRETATION OF THE FINDINGS & FURTHER RECOMMENDATIONS**

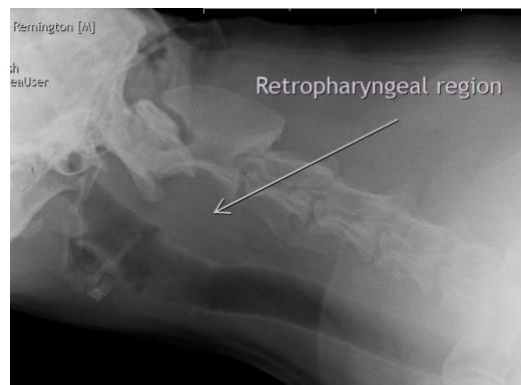
I can see no swelling and the retropharyngeal region is essentially normal. Further imaging is required to rule out foreign body which could, for instance, be a radiolucent grass seed or wood. Ultrasound of the visible mass can be performed as detection of the foreign body is most likely with this imaging tool. Otherwise, cross-sectional imaging should will have to be carried out to identify the extent and location of the lesion in case surgical exploration is necessary. The mouth should be closely inspected for penetrating wounds.

**AGE**

5 Years

**INTERPRETED BY**

Heike Rudolf, DVM,  
Dr. med. Vet.,  
DipECVDI DVR



**HOSPITAL NAME**

Lac Ste. Anne VS

**REFERRING VET**

Kristin McIntosh

**The information and recommendations provided are based on the images presented by the referring veterinarian/sonographer. No evaluation can be communicated regarding pathology that was not visible in the image/video clips provided.**

**INVOICE**

16587

Thank you for this referral. If the clinical or image interpretation does not parallel your findings or if I can be of any further assistance please contact me.

**DATE**

7/29/22

**Heike Rudolf**, DVM, Dr. med. vet., DipECVDI, DVR  
dr.h.rudorf@gmail.com



**PATIENT**

Remington Johnson

**SPECIES**

Canine

**BREED**

Labrador Retriever

**SEX**

Neutered Male

**AGE**

5 Years

**INTERPRETED BY**

Heike Rudorf, DVM,  
Dr. med. Vet.,  
DipECVDI DVR

**HOSPITAL NAME**

Lac Ste. Anne VS

**REFERRING VET**

Kristin McIntosh

**INVOICE**

16587

**DATE**

7/29/22