


PATIENT PRESENTING CLINICAL SIGNS

Petey Wendt Occasional hacking cough 2-3 days. Normal physical exam. No exposure to other pets. No other signs of illness. Grade 3 dental disease.

SPECIES Abnormal PE/Chem/CBC/UA Results: Lab work pending.

Canine RADIOGRAPHIC STUDY OF THE THORAX

BREED The body condition score is 6/9 with smooth alternating layers of fat and soft tissue opacity. Bridging, ventral spondylosis is present at T10/11.

Terrier x The degree of pulmonary expansion is good. The lungs are in contact with the thoracic boundaries and the tips are pointed. The lobar vessels are visible to the tertiary branches. The walls of the bronchial tree are slightly prominent which results in the visibility of tramlines on the lateral views.

SEX The cranial mediastinum is of physiological size and opacity. The trachea diverges from the thoracic vertebrae and dips at the carina. A soft tissue opaque line is present in/overlying the dorsal third of the tracheal lumen. This results in a variation of the height of the tracheal air shadow between 1 and 1.4cm.

Neutered Male

AGE The cardiac silhouette occupies 75% of the chest height and 3 intercostal spaces. No chamber or outflow tract enlargement is evident.

4 Years RADIOGRAPHIC DIAGNOSIS

INTERPRETED BY

- Tracheal collapse
- Bronchial pattern

Heike Rudolf, DVM,
 Dr. med. Vet.,
 DipECVDI DVR

INTERPRETATION OF THE FINDINGS & FURTHER RECOMMENDATIONS

Thickening of the bronchi is not very marked but for a 4 year old dog it is probably significant. Thus, bronchoscopy with broncho-alveolar lavage is necessary to rule out infection and inflammation.

HOSPITAL NAME

Northshore VH Tracheal collapse alone can be due to a weakened dorsal tracheal ligament. Tracheal in combination with bronchial collapse is usually due to an altered cartilage development which may go unnoticed until physical circumstances (such as stress, running, excitement) or disease (e.g. pneumonia, bronchitis, L cardiac enlargement) reduces the ease of airflow. Echocardiography to assess mitral valve and left atrial size is recommended in case a heart murmur is audible.

REFERRING VET

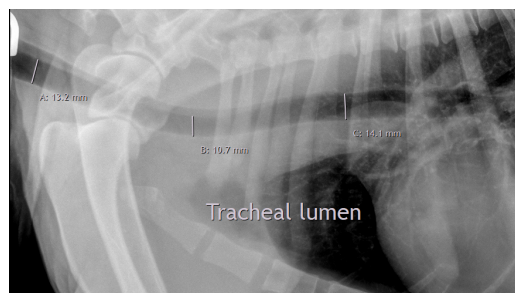
Dr. Sophie Lee

INVOICE

44395

DATE

7/26/23





PATIENT

Petey Wendt

SPECIES

Canine

BREED

Terrier x

SEX

Neutered Male

AGE

4 Years

INTERPRETED BY

Heike Rudorf, DVM,
Dr. med. Vet.,
DipECVDDI DVR

HOSPITAL NAME

Northshore VH

REFERRING VET

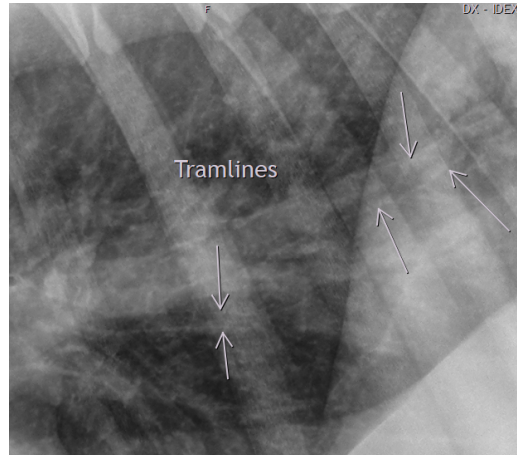
Dr. Sophie Lee

INVOICE

44395

DATE

7/26/23



The information and recommendations provided are based on the images presented by the referring veterinarian. No evaluation can be communicated regarding pathology that was not visible in the image/video clips provided.

Thank you for this referral. If the clinical or image interpretation does not parallel your findings or if I can be of any further assistance please contact me.

Heike Rudorf, DVM, Dr. med. vet., DipECVDDI, DVR
dr.h.rudorf@gmail.com