

PATIENT PRESENTING CLINICAL SIGNS

Estella Zaheer Patient has a mild fever and coughing, mild grade heart murmur.
Abnormal PE/Chem/CBC/UA Results: Blood work results pending

SPECIES RADIOGRAPHIC STUDY OF THE THORAX

Canine The body condition score is 6/9 with smooth alternating layers of fat and soft tissue opacity.
The bony structures appear physiological.

BREED

Samoyed

The degree of pulmonary expansion is very good. The lungs are in contact with the thoracic boundaries and the tips are pointed. The lobar vessels are visible to the tertiary branches. The bronchial tree is thick walled and doughnuts as well as tramlines are appreciated.

SEX

Female

The cranial mediastinum is of physiological size and opacity. The trachea diverges from the thoracic vertebrae and dips at the carina; in left lateral recumbency a dorsal tracheal stripe sign is present, and a moderate amount of air fills the entire esophagus.

AGE

11 Years

The cardiac silhouette occupies 75% of the chest height and 2.5 intercostal spaces. No chamber or outflow tract enlargement is evident.

A moderate amount of air is present in the stomach.

RADIOGRAPHIC DIAGNOSIS

- Bronchial pattern
- Air in esophagus/megaesophagus

INTERPRETED BY

Heike Rudolf, DVM,
Dr. med. Vet.,
DipECVDI DVR

INTERPRETATION OF THE FINDINGS & FURTHER RECOMMENDATIONS

HOSPITAL NAME

Truscott AH

The lung pattern indicates bronchitis. Primary inflammatory, non-infectious causes (e.g. neutrophilic, eosinophilic, allergic), as well as infectious causes (bacterial, viral, parasitic) have to be considered. Bronchoscopy including broncho-alveolar lavage is necessary for a definitive diagnosis. Transient tracheal and/or bronchial collapse can only be observed during tracheoscopy. Esophageal and gastric air could be due to stress during radiography or indicate persistent aerophagia caused by the lung disease.

REFERRING VET

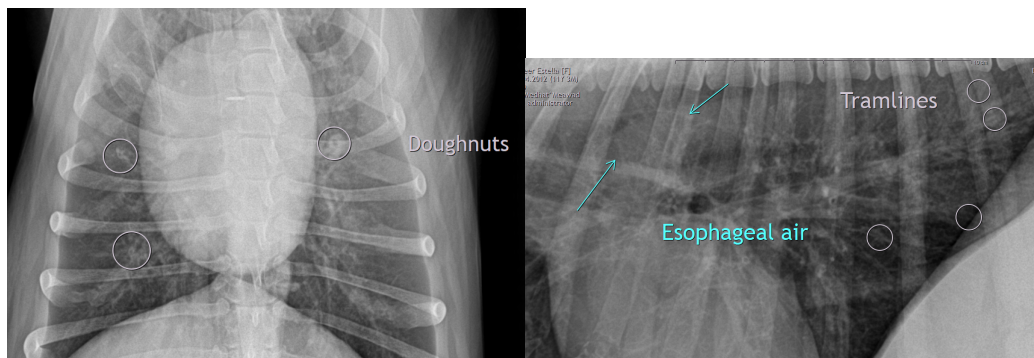
Dr. Medhat Meawad

INVOICE

44394

DATE

7/26/23





PATIENT

Estella Zaheer

The information and recommendations provided are based on the images presented by the referring veterinarian. No evaluation can be communicated regarding pathology that was not visible in the image/video clips provided.

SPECIES

Canine

Thank you for this referral. If the clinical or image interpretation does not parallel your findings or if I can be of any further assistance please contact me.

BREED

Samoyed

Heike Rudolf, DVM, Dr. med. vet., DipECVDI, DVR
dr.h.rudorf@gmail.com

SEX

Female

AGE

11 Years

INTERPRETED BY

Heike Rudolf, DVM,
Dr. med. Vet.,
DipECVDI DVR

HOSPITAL NAME

Truscott AH

REFERRING VET

Dr. Medhat Meawad

INVOICE

44394

DATE

7/26/23