



PATIENT PRESENTING CLINICAL SIGNS

Kilo Carrero History: 2 week history of P waking up between 3-5am and coughing for a short bit. Is non-productive, dry and quiet. Only lasts a few seconds.

SPECIES Abnormal PE/Chem/CBC/UA Results: PE unremarkable - no cough on tracheal palpation and lungs auscultate clear. Started cough tabs and Tamaril-P.

Canine RADIOGRAPHIC STUDY OF THE THORAX

BREED The body condition score is 8/9 with smooth alternating layers of fat and soft tissue opacity.

Chihuahua The bony structures appear physiological.

SEX The lungs are in contact with the thoracic boundaries and the tips are pointed. The lobar vessels are clearly visible to the tertiary branches. The bronchial tree is thin walled and tapers uniformly towards the periphery.

Neutered Male The cranial mediastinum is of physiological size and opacity. The trachea diverges slightly from the thoracic vertebrae and dips at the carina. The tracheal air shadow is slightly larger in the cervical region.

AGE The cardiac silhouette occupies 75% of the chest height and 3 intercostal spaces (VHS 10.25). No chamber or outflow tract enlargement is evident.

7 Years RADIOGRAPHIC DIAGNOSIS

- Obesity

INTERPRETED BY INTERPRETATION OF THE FINDINGS & FURTHER RECOMMENDATIONS

Heike Rudorf, DVM, Dr. med. Vet., DipECVDDI DVR I can see no pulmonary changes. However, bronchitis can be present without radiographic evidence. Furthermore, airway collapse can be present. Bronchial may precede tracheal collapse and is usually caused by chondromalacia which is due to an altered cartilage development and may go unnoticed until physical circumstances (such as stress, running, excitement) or disease (e.g. pneumonia, bronchitis, L cardiac enlargement) reduces the ease of airflow. Echocardiography to assess mitral valve as well as L atrial size and bronchoscopy to obtain a BAL is recommended if the clinical signs are progressing. Should an underlying disease be present, treatment may improve the clinical signs.

HOSPITAL NAME Boca Park AH

REFERRING VET Obesity is known to worsen clinical signs of cough and impair lung function; weight control is recommended.

Dr. Hill

INVOICE

16725

DATE

7/22/22



PATIENT

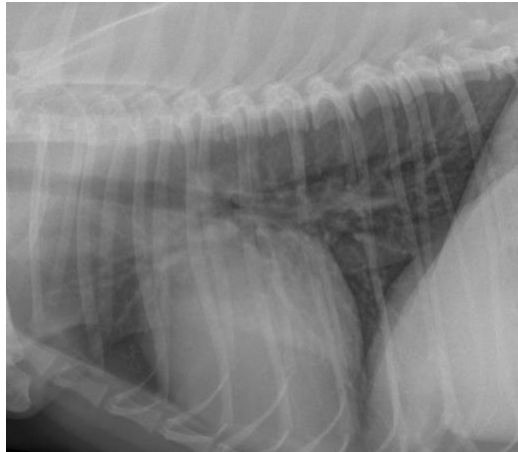
Kilo Carrero

SPECIES

Canine

BREED

Chihuahua



Physiological lung pattern

SEX

Neutered Male

The information and recommendations provided are based on the images presented by the referring veterinarian/sonographer. No evaluation can be communicated regarding pathology that was not visible in the image/video clips provided.

AGE

7 Years

Thank you for this referral. If the clinical or image interpretation does not parallel your findings or if I can be of any further assistance please contact me.

Heike Rudorf, DVM, Dr. med. vet., DipECVDI, DVR
dr.h.rudorf@gmail.com

INTERPRETED BY

Heike Rudorf, DVM,
Dr. med. Vet.,
DipECVDI DVR

HOSPITAL NAME

Boca Park AH

REFERRING VET

Dr. Hill

INVOICE

16725

DATE

7/22/22