



PATIENT PRESENTING CLINICAL SIGNS

Pepper Bennet History: Radioulnar fractured that occurred 7/8/2023. Was set with a splint and bandaged. Presented today to recheck rads and change bandage. Bandage has been wet the last 2 days because Pepper played in the water bowl.

SPECIES Abnormal PE/Chem/CBC/UA Results: Cutaneous wounds due to splint. Normal otherwise.

Canine **RADIOGRAPHIC STUDY OF THE ELBOWS**

BREED The skin surfaces are smooth and a mild soft tissue swelling surrounds the fracture sites. Skeletal immaturity compatible with the given age is noted.

Catahoula Leopard Dog Mix Obvious horizontal fracture lines are visible in mid radius and ulna. Marked periosteal new bone is present on both sides of the fracture line in both bones and forms a smooth triangle on the lateral view. The new bone is more prominent on the cranial aspect due to the mild caudal angulation of the fractures. A fine line of calcification is trying to bridge the ulnar gap caudally. The fracture lines show an inhomogeneous lucency suggesting bridging new bone formation.

SEX

Female **RADIOGRAPHIC DIAGNOSIS**

- Fracture mid-diaphysis radius and ulna
- Healing in progress

AGE

5 Months

INTERPRETED BY

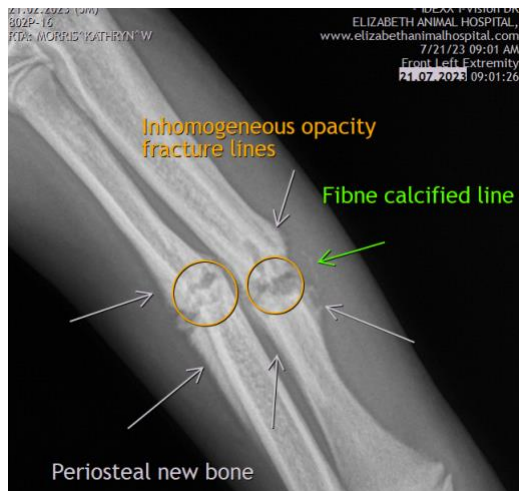
Heike Rudorf, DVM,
Dr. med. Vet.,
DipECVDI DVR

HOSPITAL NAME

Elizabeth AH

REFERRING VET

Leon Anderson, DVM



The information and recommendations provided are based on the images presented by the referring veterinarian/sonographer. No evaluation can be communicated regarding pathology that was not visible in the image/video clips provided.

INVOICE

23595

Thank you for this referral. If the clinical or image interpretation does not parallel your findings or if I can be of any further assistance please contact me.

Heike Rudorf, DVM, Dr. med. vet., DipECVDI, DVR

DATE

7/21/23



PATIENT info@sonopath.com

Pepper Bennet

SPECIES

Canine

BREED

Catahoula Leopard
Dog Mix

SEX

Female

AGE

5 Months

INTERPRETED BY

Heike Rudorf, DVM,
Dr. med. Vet.,
DipECVDI DVR

HOSPITAL NAME

Elizabeth AH

REFERRING VET

Leon Anderson, DVM

INVOICE

23595

DATE

7/21/23