



PATIENT PRESENTING CLINICAL SIGNS

Ollie Barrett History: Possible FB, vomiting on and off for about 1 week. Lethargic, loss of appetite, drinking well. CBC, CHEM, T4, FPL WNL

SPECIES RADIOGRAPHIC STUDY OF THE ABDOMEN

Feline The body condition score is 7/9 with smooth alternating layers of fat and soft tissue opacity.
The bony structures are within normal limits.

BREED The abdominal detail is good; diaphragm and abdominal wall are intact.

DSH The liver is located within the costal arch and the caudo-ventral lobe is pointed.
The spleen appears physiological.

SEX The stomach contains a small amount of air and the wall of the fundus is approx. 0.7cm thick; distribution and size of the small intestinal loops appear physiological. Colon and rectum contain a small amount of fecal matter. The dorsal aspect of the terminal colon is indistinguishable from the sublumbar region.
Neutered Male

AGE The left renal shadow has a physiological size, shape and opacity; the right is obscured by intestinal loops but appears to be of normal size on the lateral view. The bladder is located in the abdominal cavity and contains a moderate amount of homogeneous fluid opacity.
2 Years

INTERPRETED BY The physiological sublumbar soft tissue opacity fuses with the empty colon.

Heike Rudolf, DVM,
Dr. med. Vet.,
DipECVDI DVR

RADIOGRAPHIC DIAGNOSIS

- Gastric wall thickening

INTERPRETATION OF THE FINDINGS & FURTHER RECOMMENDATIONS

HOSPITAL NAME I can see no radiopaque foreign body. Thickening of the gastric wall is subjective because the stomach is collapsed and only contains a small amount of air. However, chronic gastritis secondary to chronic vomiting may be present. Should conservative therapy not improve the clinical signs, gastroscopy is recommended to obtain full thickness biopsies to rule out eosinophilic or lymphoma infiltrate. Assessment of the sublumbar lymph nodes will have to be performed ultrasonographically because of their close proximity to the empty colon.
Williamsport West VH

REFERRING VET
Stephanie Daverio,
DVM

INVOICE

23594

DATE

7/21/23



PATIENT

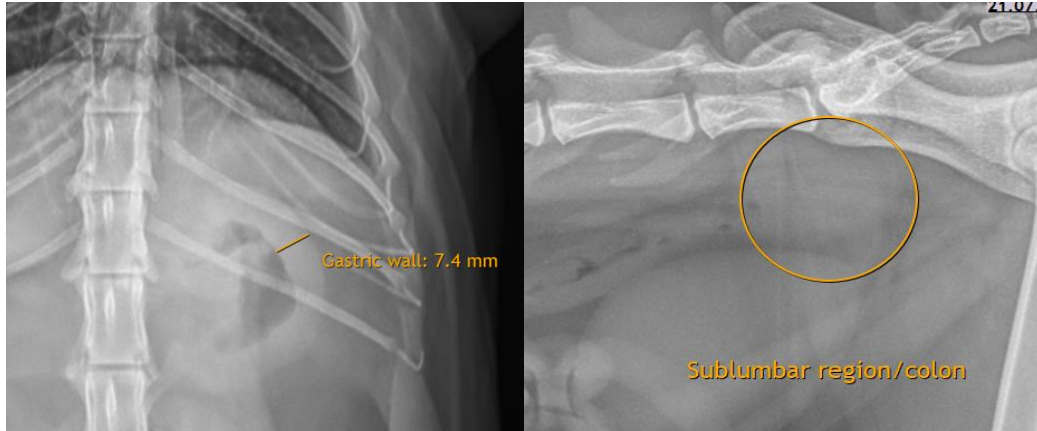
Ollie Barrett

SPECIES

Feline

BREED

DSH



SEX

Neutered Male

AGE

2 Years

The information and recommendations provided are based on the images presented by the referring veterinarian/sonographer. No evaluation can be communicated regarding pathology that was not visible in the image/video clips provided.

Thank you for this referral. If the clinical or image interpretation does not parallel your findings or if I can be of any further assistance please contact me.

Heike Rudolf, DVM, Dr. med. vet., DipECVDI, DVR
info@sonopath.com

INTERPRETED BY

Heike Rudolf, DVM,
Dr. med. Vet.,
DipECVDI DVR

HOSPITAL NAME

Williamsport West VH

REFERRING VET

Stephanie Daverio,
DVM

INVOICE

23594

DATE

7/21/23