



**PATIENT PRESENTING CLINICAL SIGNS**

Ollie Rowe History: Unable to weight bare on right hind leg. Drawer test is negative. Need to rule out any other musculoskeletal abnormality.

**SPECIES RADIOGRAPHIC STUDY OF STIFLES AND TARSI**

Canine The skin surfaces are smooth and the muscles appear to be symmetrically developed.

All bones are well mineralized, have a normal trabecular structure and a smooth surface. Cortical-medullary development and differentiation of the long bones are physiological.

**BREED**

Australian Shepherd X Both stifle joints have smooth subchondral bone surfaces and the centre of the femoral condyles is in line with the intercondylar eminence. The cranial fat pad has a physiological size and the caudal fascial plains are in a physiological position. New bone formation is not evident and the left patella is located in its groove. The right stifle joint is oblique on all VD pelvis views and thus the patella never centrally located.

**SEX**

Neutered Male The hock joints appear physiological on both sides.

**RADIOGRAPHIC DIAGNOSIS**

- I can see no convincing abnormalities.

**AGE**

3 Years

**INTERPRETATION OF THE FINDINGS & FURTHER RECOMMENDATIONS**

A lateral patella luxation is unlikely in this breed but manual examination will allow accurate assessment. Muscle, e.g. myositis or partial tear of one of the gastrocnemius muscle bellies, or digital tendon injuries are potential diagnoses. Thus, contrast CT is recommended.

**INTERPRETED BY**

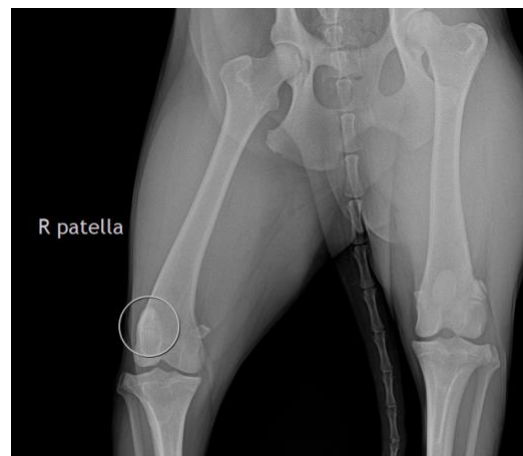
Heike Rudorf, DVM,  
Dr. med. Vet.,  
DipECVDI DVR

**HOSPITAL NAME**

Truscott AH

**REFERRING VET**

Dr. Medhat Meawad



**INVOICE**

23590

**The information and recommendations provided are based on the images presented by the referring veterinarian/sonographer. No evaluation can be communicated regarding pathology that was not visible in the image/video clips provided.**

**DATE**

7/20/23



**PATIENT**

Ollie Rowe

Thank you for this referral. If the clinical or image interpretation does not parallel your findings or if I can be of any further assistance please contact me.

**SPECIES**

Canine

**Heike Rudolf**, DVM, Dr. med. vet., DipECVDI, DVR  
info@sonopath.com

**BREED**

Australian Shepherd  
X

**SEX**

Neutered Male

**AGE**

3 Years

**INTERPRETED BY**

Heike Rudolf, DVM,  
Dr. med. Vet.,  
DipECVDI DVR

**HOSPITAL NAME**

Truscott AH

**REFERRING VET**

Dr. Medhat Meawad

**INVOICE**

23590

**DATE**

7/20/23