



PATIENT PRESENTING CLINICAL SIGNS

Zorro Corrales History: Owner reports 3 years of coughing on and off, more frequently in the past few weeks when getting excited. Overweight. Otherwise doing well.
Abnormal PE/Chem/CBC/UA Results: Overweight.

SPECIES RADIOGRAPHIC STUDY OF THE THORAX

Canine The body condition score is 8/9 with a large amount of dorsal subcutaneous fat.

BREED The bony structures appear physiological.

Pomeranian The lungs are slightly removed from the rib cage by fat; the tips are pointed. The degree of pulmonary expansion is fair at best. The lobar vessels are visible on the DV view.

SEX The cranial mediastinum is of physiological size and opacity. The trachea runs parallel to the thoracic vertebrae and dips slightly at the carina.

Neutered Male

The cardiac silhouette occupies 75% of the chest height and 3.5 intercostal spaces. On the lateral view the region of the left atrium (LA) appears enlarged. This is not obvious on the DV view.

AGE RADIOGRAPHIC DIAGNOSIS

9 Years 9 Months

- Poor lung expansion
- Possible LA enlargement
- Obesity

INTERPRETED BY

Heike Rudolf, DVM,
Dr. med. Vet.,
DipECVDI DVR

INTERPRETATION OF THE FINDINGS & FURTHER RECOMMENDATIONS

The poor lung expansion in combination with the interstitial pattern could be due to obesity. Possible differential diagnoses for a true infiltrate include:

HOSPITAL NAME

Pocono Peak VC

- Fibrosis
- Inflammation (allergic e.g. eosinophilic bronchopneumonia and PIE, smoke inhalation)
- Infection (bacterial, fungal e.g. candida, viral, Rickettsia, Spirochetes, parasitic)
- Edema
- Hemorrhage
- Tumor (e.g. lymphoma)

REFERRING VET

Dr. Nicole Norris-
Carney

The long history of coughing, however, makes edema, haemorrhage and tumour unlikely. Chronic inflammation due to an allergic response are more likely and could have resulted in an early pulmonary fibrosis. If lung resistance is persistently high, tracheal and/or bronchial collapse can become apparent and contribute to the problem. Fibrosis is best diagnosed when comparing the end-inspiratory (best obtained under G.A. with ventilation) with an end-expiratory views where the location of the diaphragm does not change.

INVOICE

16673

DATE

7/15/22



PATIENT

The impression of a left atrial enlargement should be verified with echocardiography, which will also be able to detect early pulmonary hypertension.

Zorro Corrales

Obesity is known to worsen clinical signs of cough and impair lung function; weight control is strongly recommended.

SPECIES

Canine

BREED

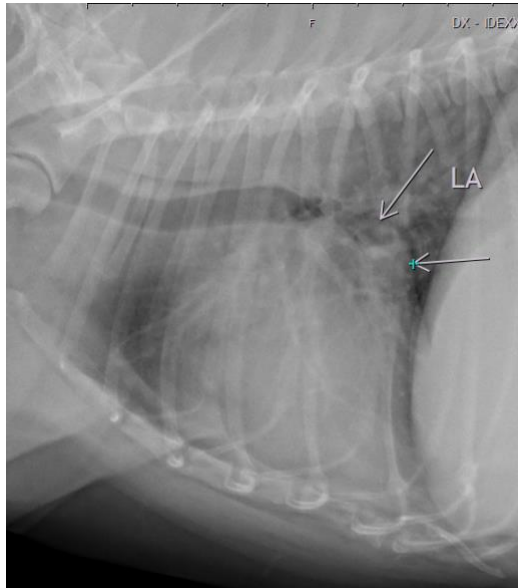
Pomeranian

SEX

Neutered Male

AGE

9 Years 9 Months



INTERPRETED BY

The information and recommendations provided are based on the images presented by the referring veterinarian/sonographer. No evaluation can be communicated regarding pathology that was not visible in the image/video clips provided.

Heike Rudolf, DVM,
Dr. med. Vet.,
DipECVDI DVR

Thank you for this referral. If the clinical or image interpretation does not parallel your findings or if I can be of any further assistance please contact me.

HOSPITAL NAME

Pocono Peak VC

Heike Rudolf, DVM, Dr. med. vet., DipECVDI, DVR
dr.h.rudorf@gmail.com

REFERRING VET

Dr. Nicole Norris-
Carney

INVOICE

16673

DATE

7/15/22